Histology of Bone

Dr Punita Manik
Professor
Department of Anatomy
K G Medical University UP
Lucknow

Objectives

- Introduction
- Functions of Bone
- Composition of Bones
- Classification of Bones
- Histology of Bones
- Clinical

Bone

- Is a rigid form of scleral **connective tissue** in which the extracellular matrix is impregnated with inorganic salts mainly calcium, phosphate and carbonate, providing hardness

Rigidity and hardness is provided by the matrix which is impregnated with inorganic salts

Functions

- Forms skeletal framework
- Attachment to muscles
- Serves as lever for muscular actions
- Bears body weight
- Protects vital organs
- Stores calciuum, phoshate and other ions
- Contains haemopoietic tissue, the bone marrow

Composition of Bone

- 1.Cells -Osteoprogenitor cells
- - Osteoblast
  - Osteocyte
  - Osteoclast
- 2.Fibres(95%)-

  -collagen fibre Type1
- 3.Ground substance(5%)

  Inorganic Part

  -Calcium phosphate 85%

  -calcium carbonate 10%

  Organic Part:

  - Collagen
  - Ground substance

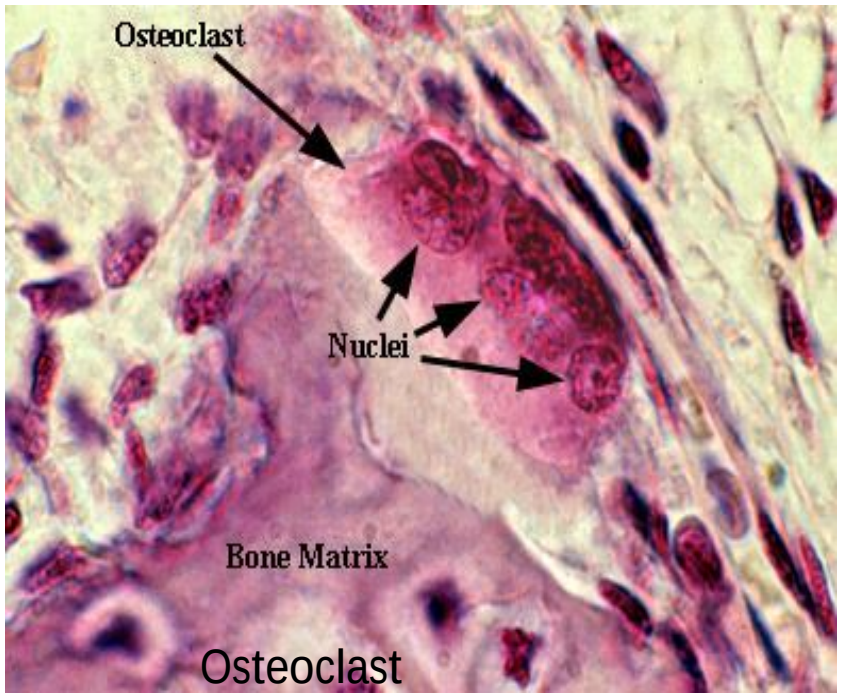

Osteoclast

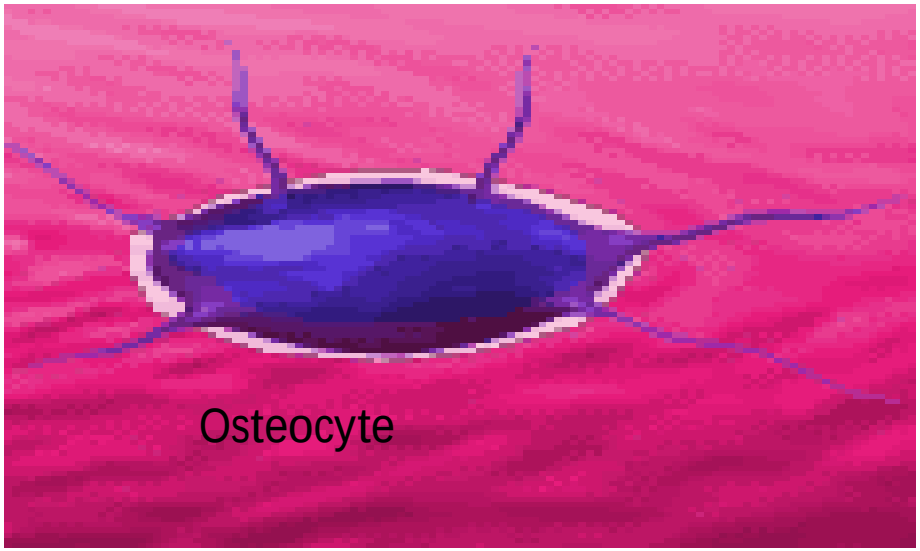
Osteocyte

Cells of Bone

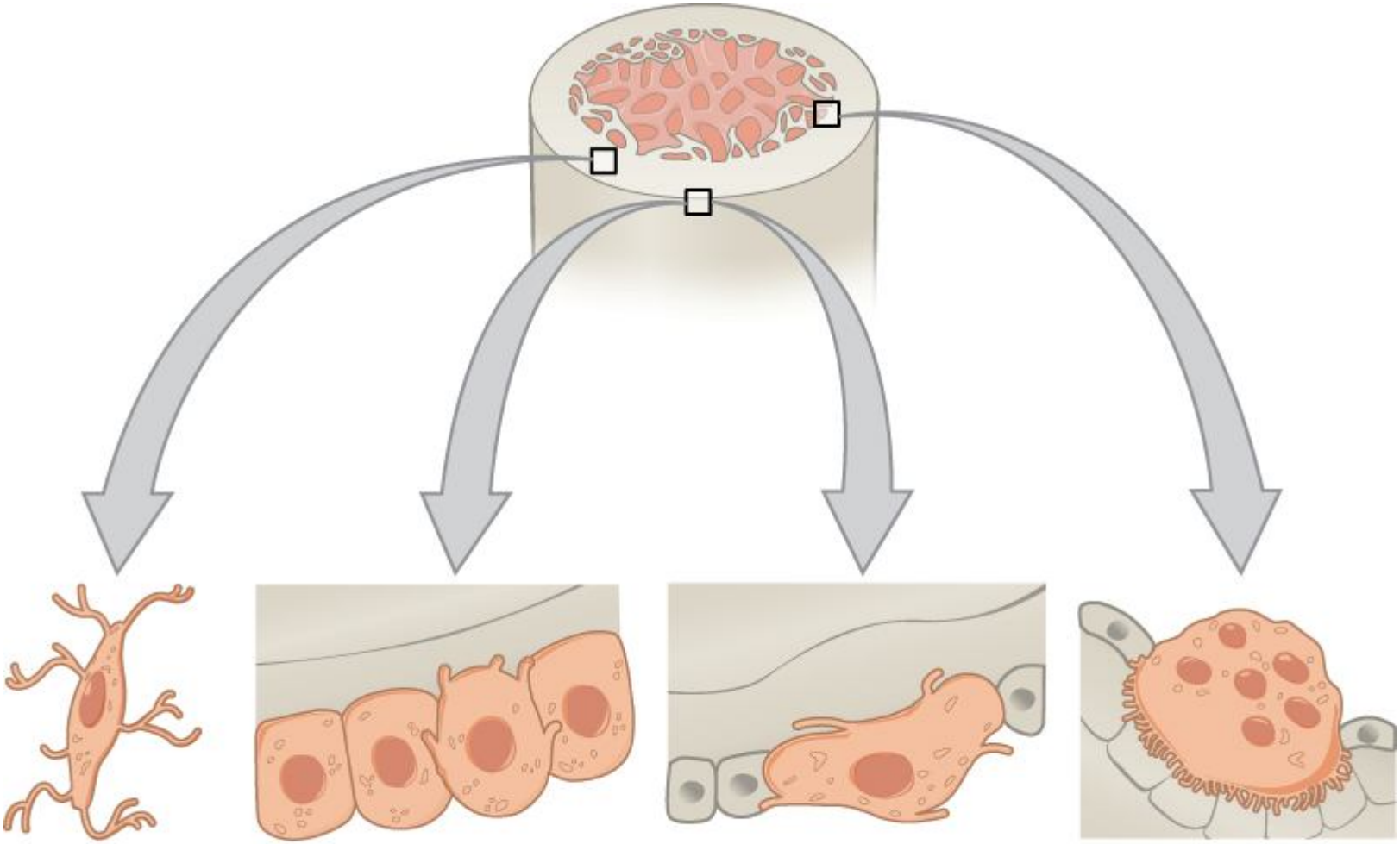

Osteocyte
(maintains bone tissue)

Osteoblast
(forms bone matrix)

Osteogenic cell
(stem cell)

Osteoclast
(resorbs bone)

Bone Cells

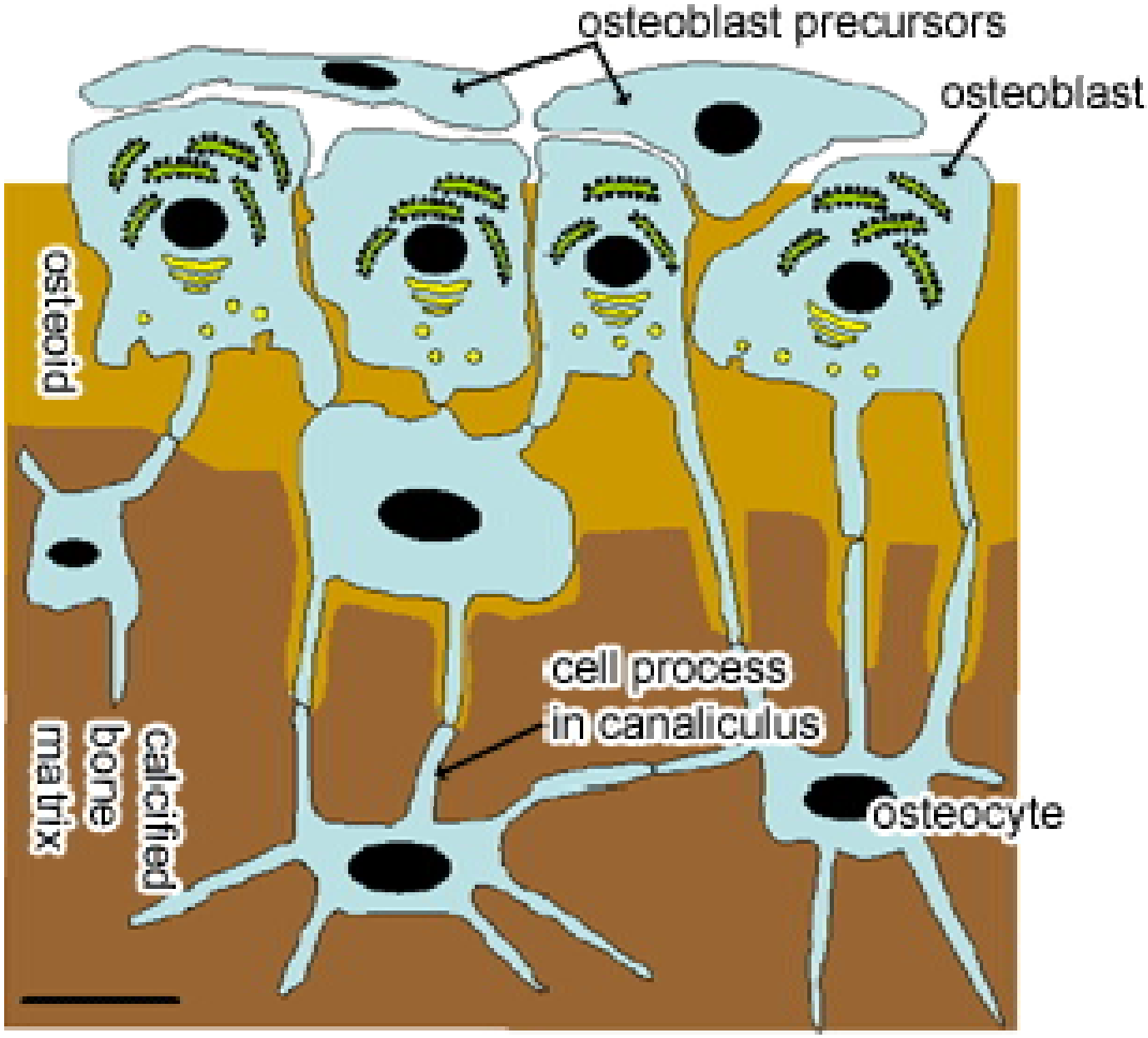
osteoid
calcified bone matrix
cell process in canaliculus
osteocyte
osteoblast precursors
osteoblast

Function of Bone Cells

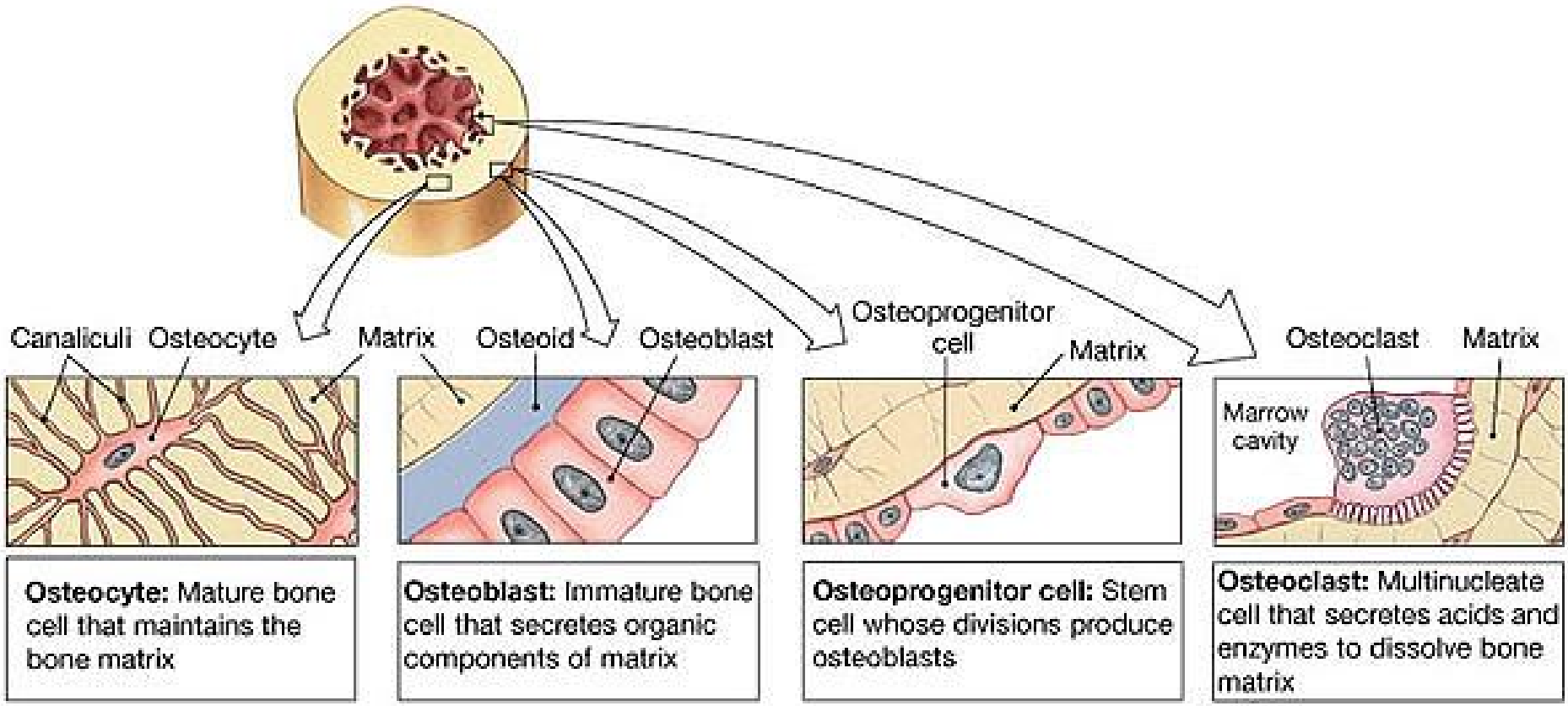

Newly formed unmineralized bone....OSTEOID

Osteoclasts are seen in specialized depression.....Howship's Lacunae

Osteoclast

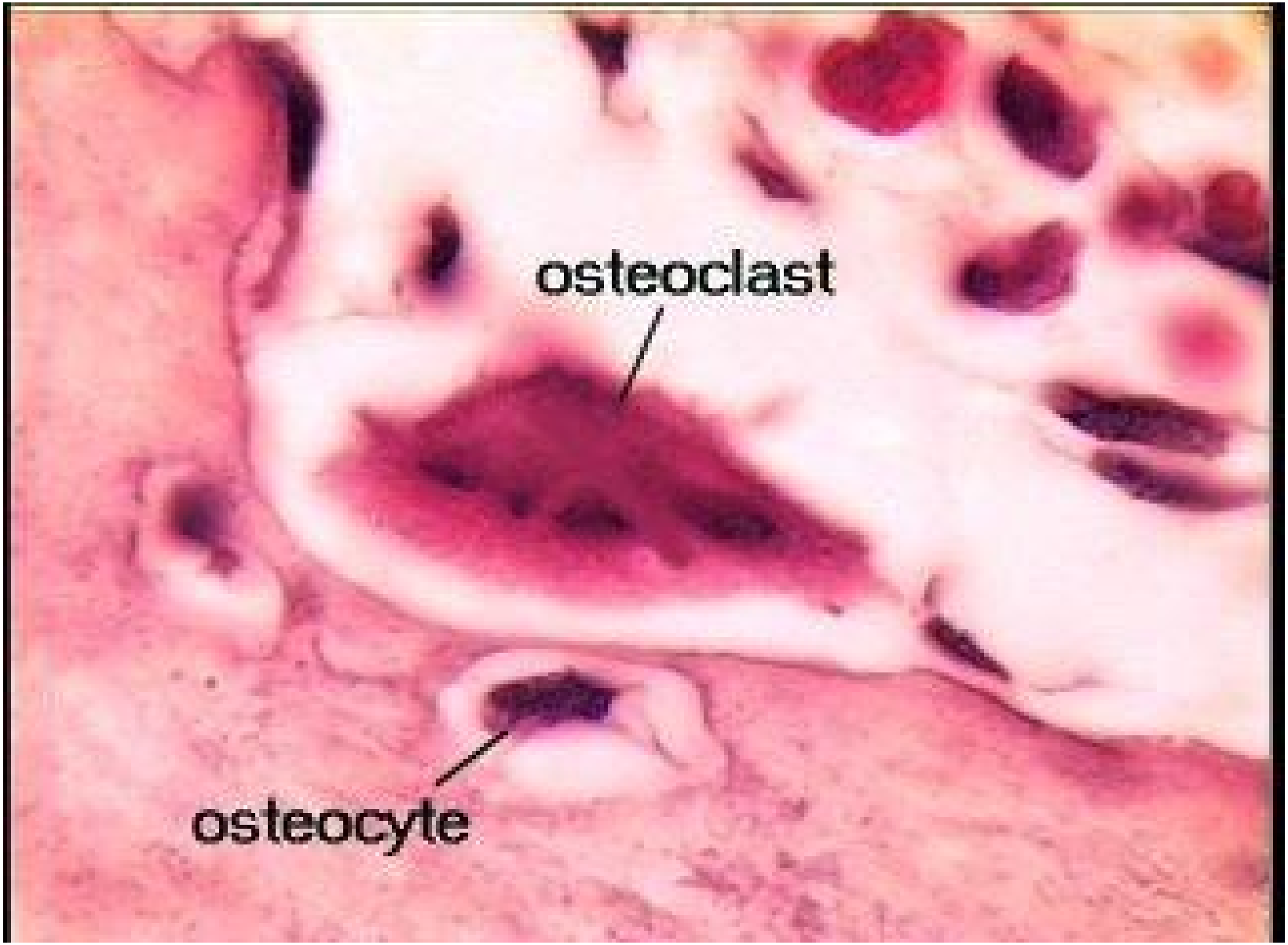

Bone Membranes

- **Periosteum**
- **Endosteum**

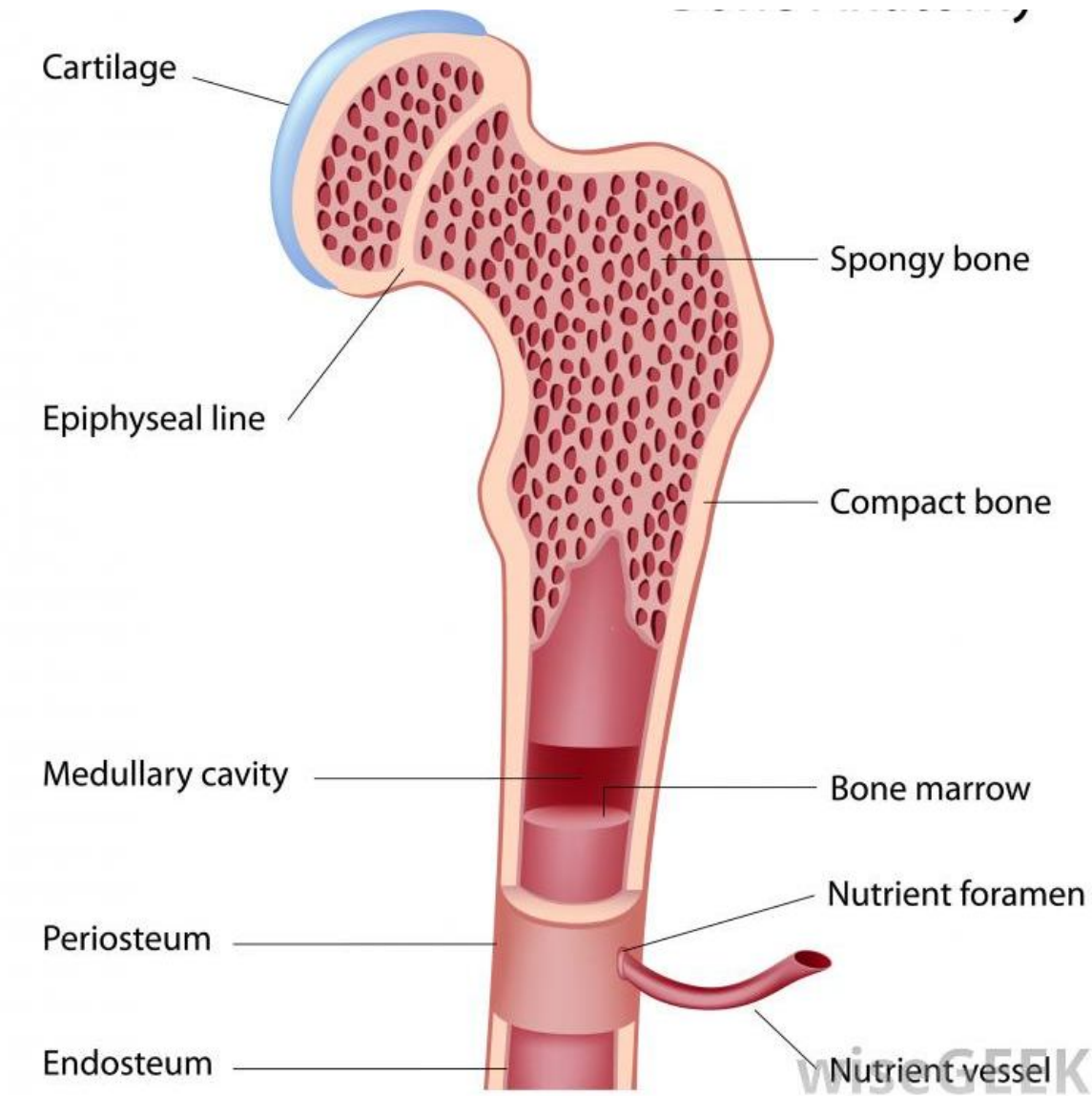

Bone Membranes

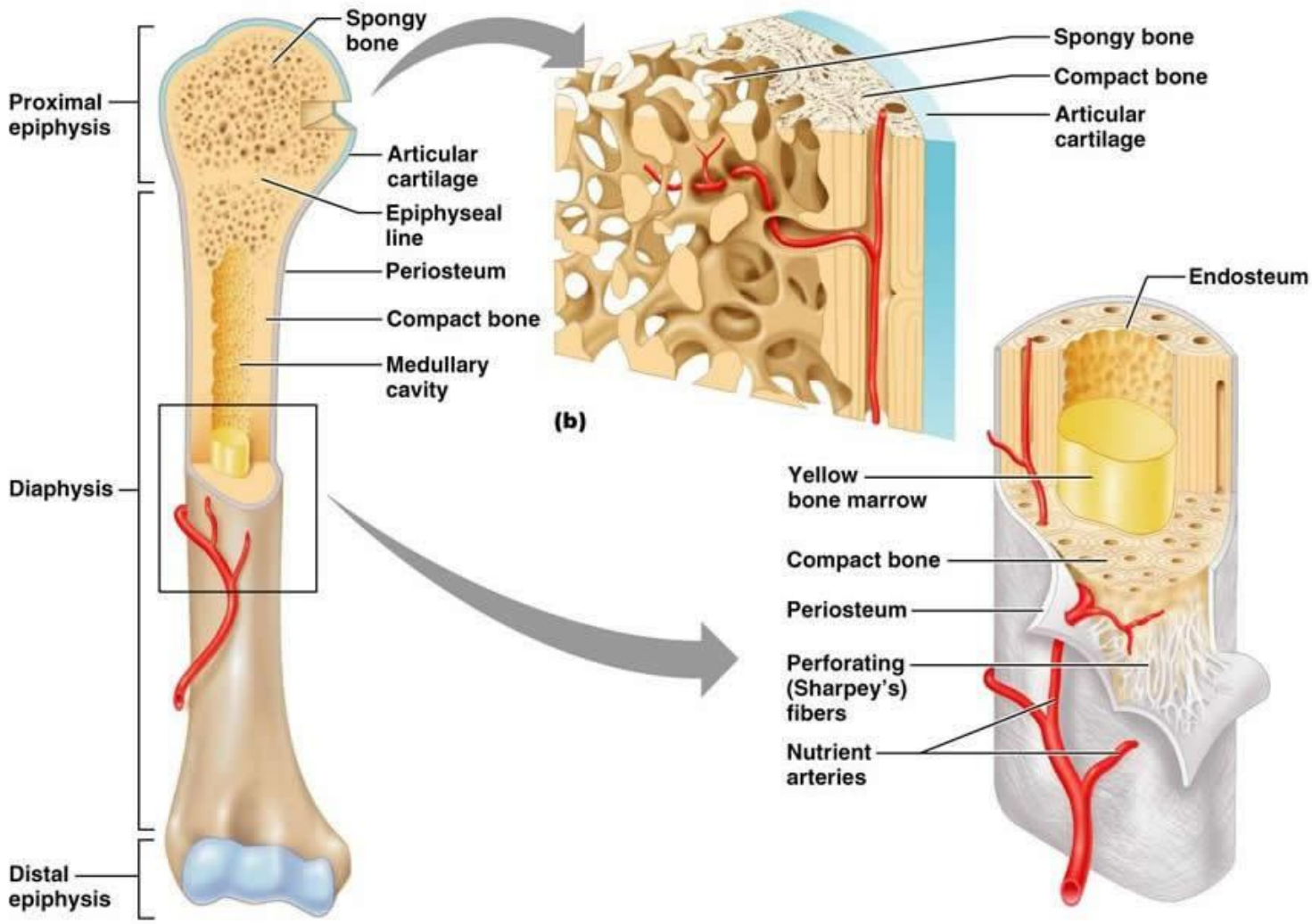

Types of Bones

Morphologically:

- Compact Bone and Spongy or cancellous Bone

Arrangement of Collagen Bundles:

- Lamellar and Woven Bone

Developmentally:

- Cartilage Bone and membrane Bone

Compact and Spongy bone

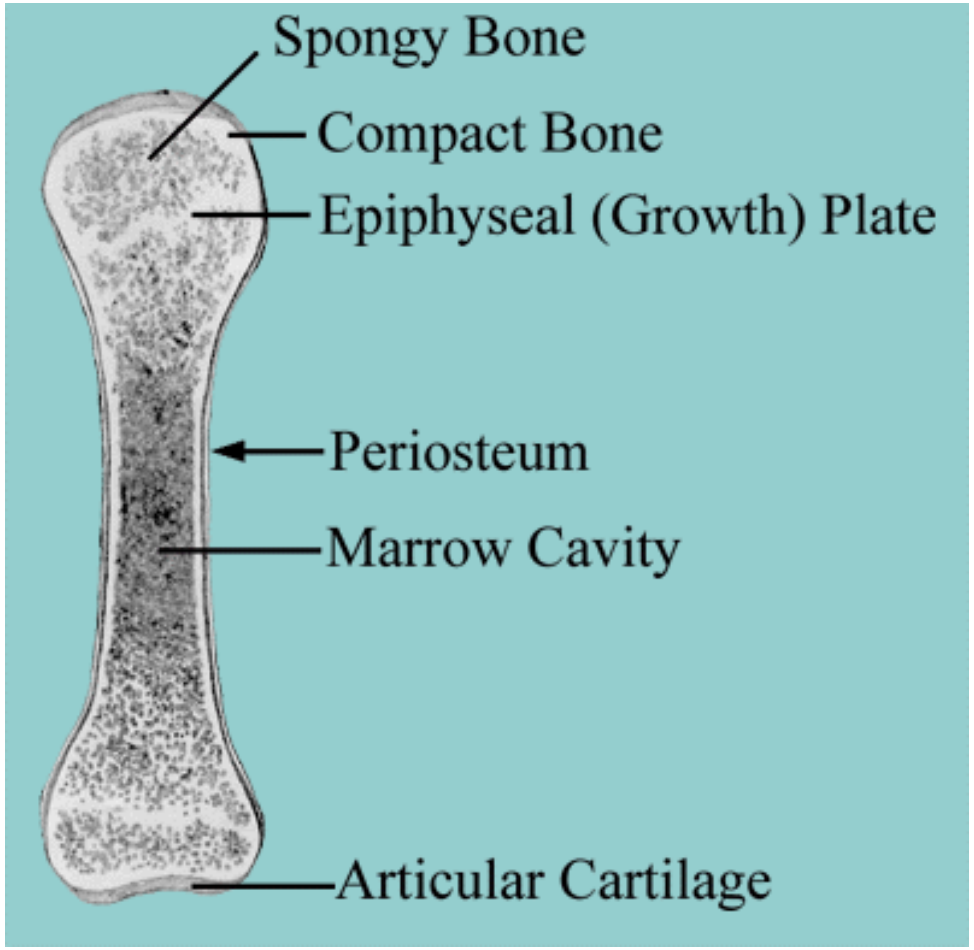

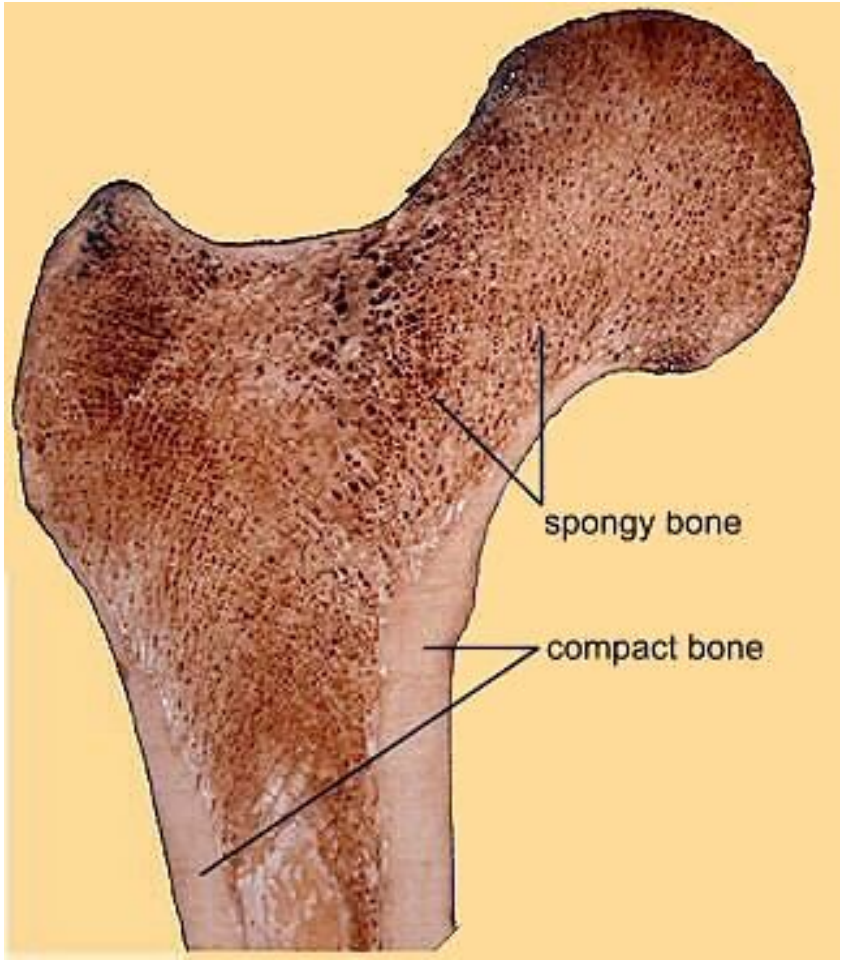

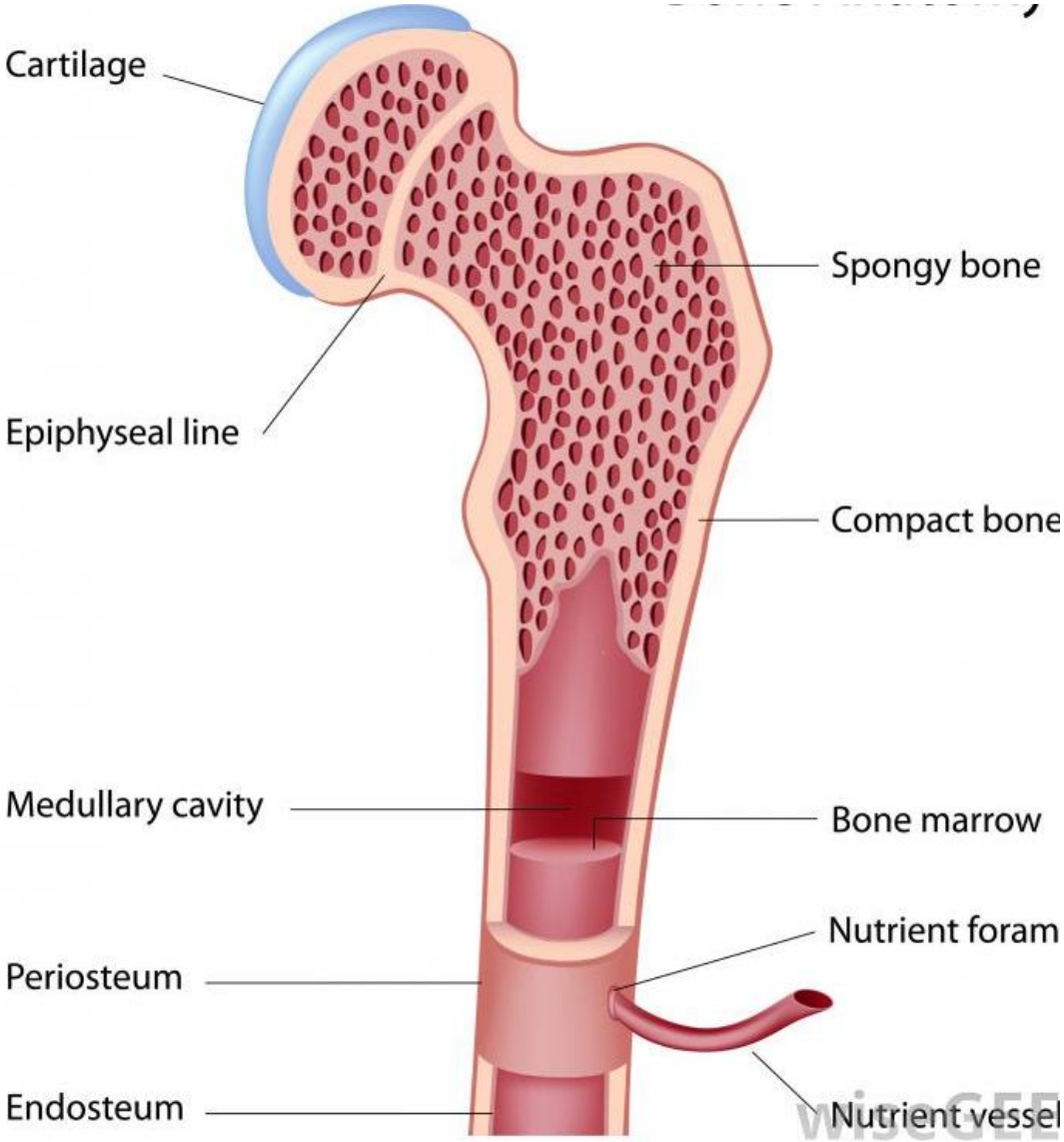
Cartilage
Spongy bone
Epiphyseal line
Compact bone
Medullary cavity
Bone marrow
Nutrient foram
Periosteum
Endosteum
Nutrient vessel

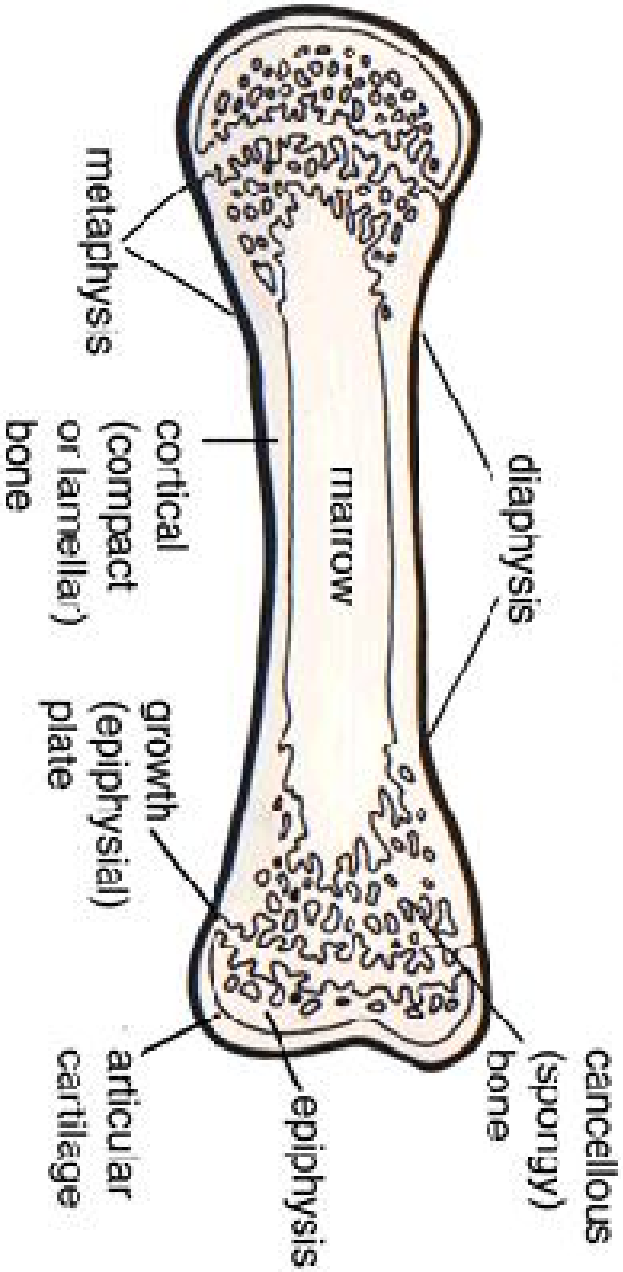
metaphysis
cortical (compact or lamellar) bone
marrow
diaphysis
growth (epiphysial) plate
cancellous (spongy) bone
articular cartilage
epiphysis

Structure of Compact Bone

- **Circumferential System**
  - Periosteal
  - Endosteal
- **Haversian System**: Most Characteristic feature. Also Known as **OSTEON**: IS the Structural and Functional unit
- **Interstitial System**

Haversian and Volkmann's Canal

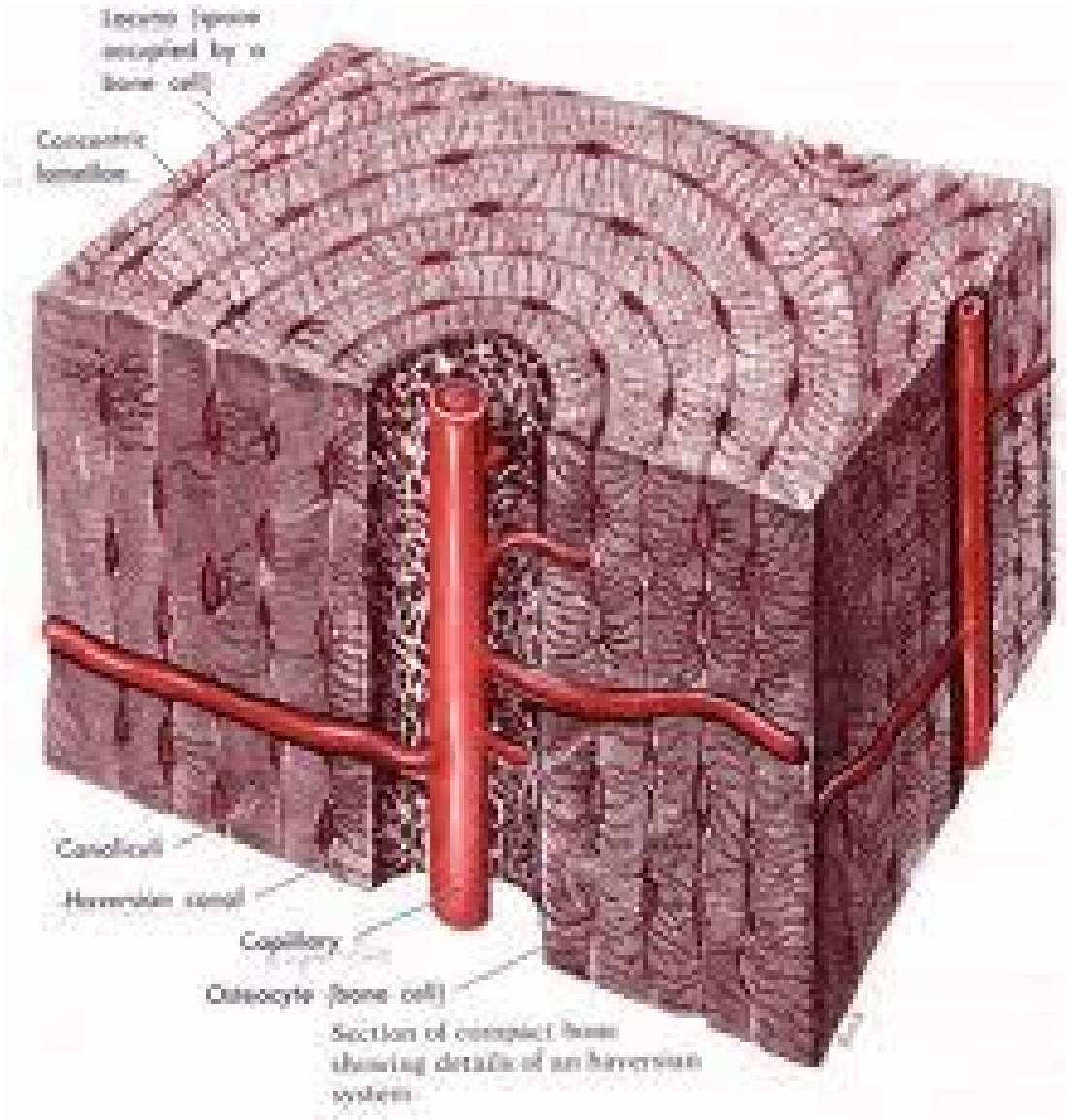

Longitudinal section of Haversian Canals and Horizontal sections of Volkmann's Canal

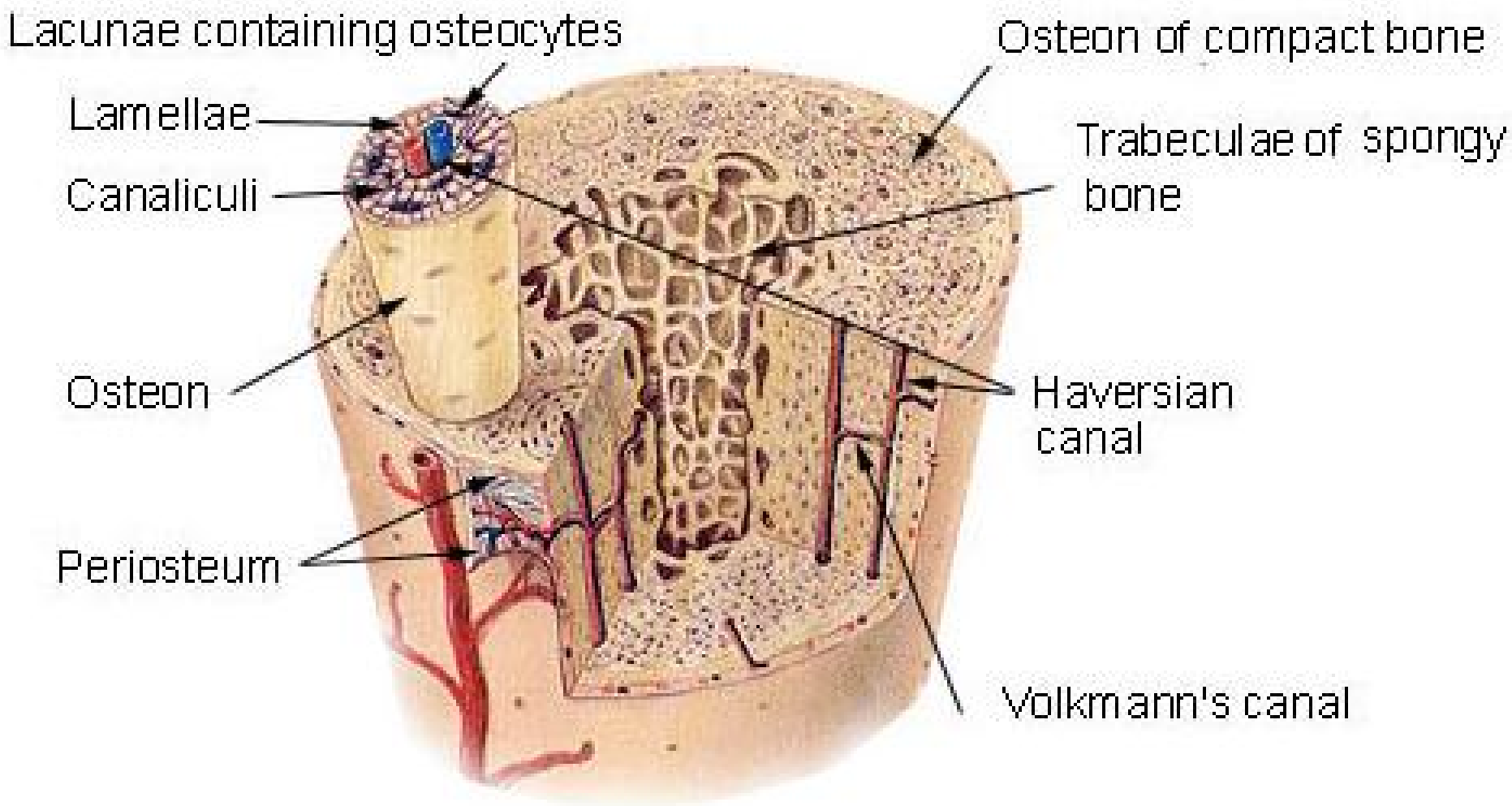

Compact bone

The **osteon** is a unit of structure consisting of **concentric lamellae** surrounding an **haversian canal**.

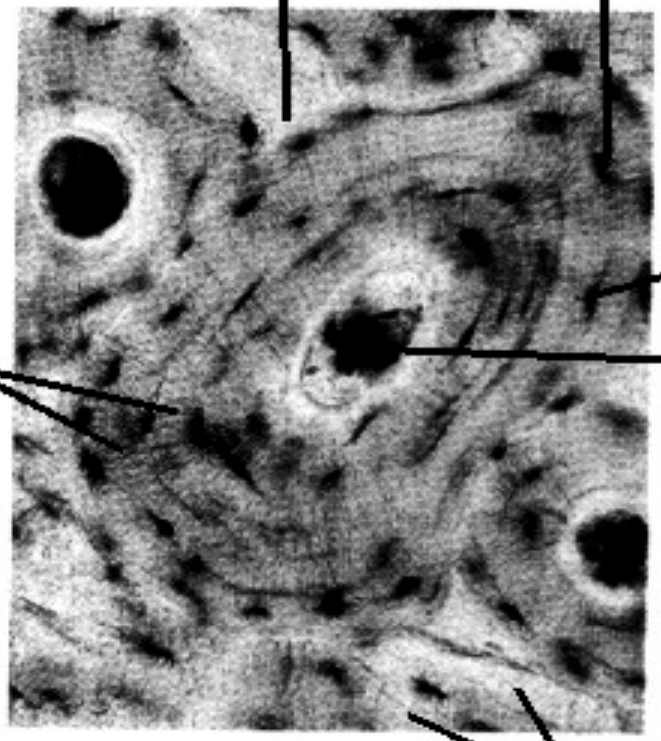

Lacunae are spaces enclosing the bone cells, or osteocytes.

Haversian canals run longitudinally through bone allowing passage of small blood vessels.

The tiny "hairs" are small canaliculi which allow extensions of the **osteocytes** to reach out and obtain nutrients and even form contacts with one another.

Interstitial lamellae are non-circular remnants left behind from former osteons when new osteons replace them.

Compact Bone

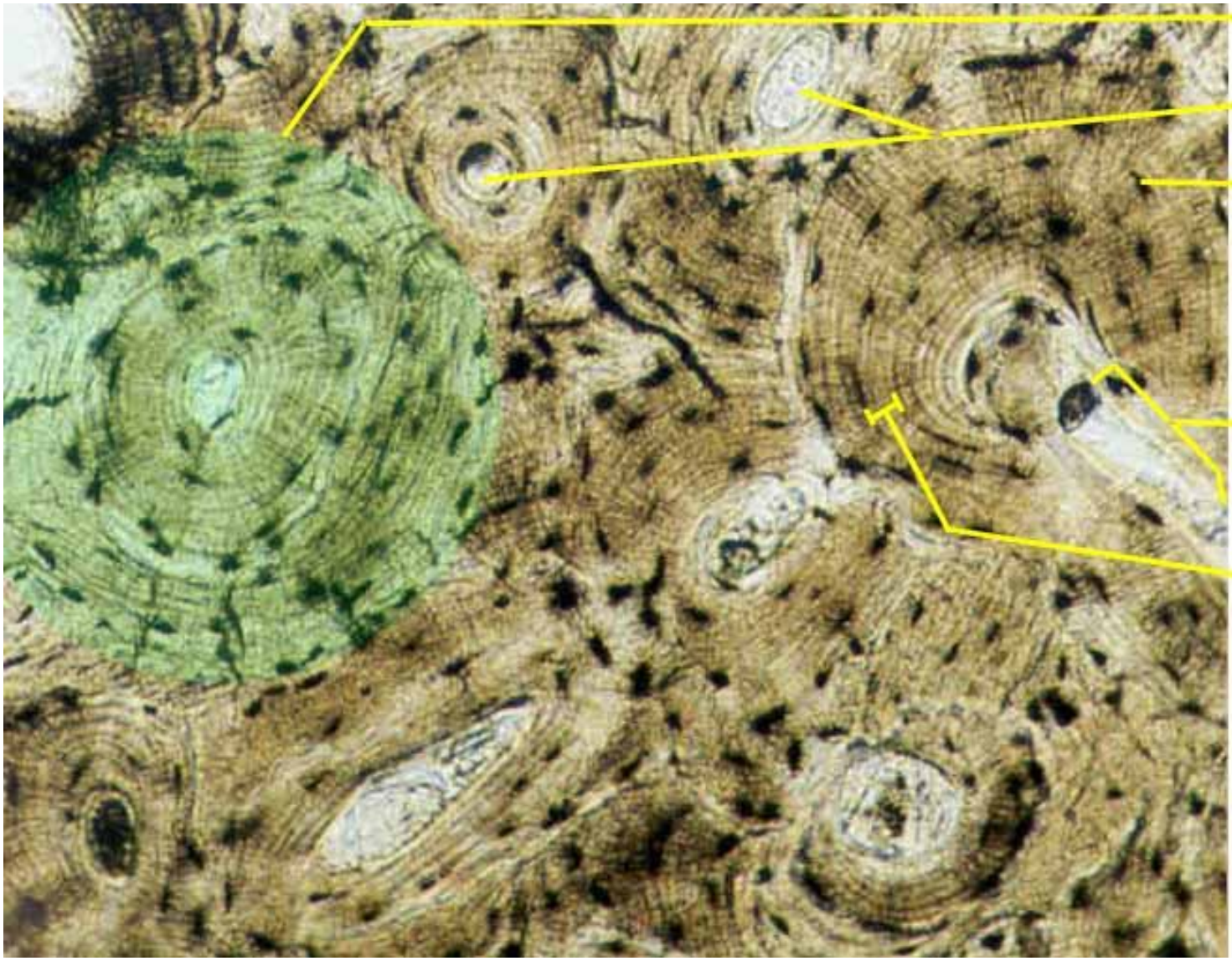

Compact Bone

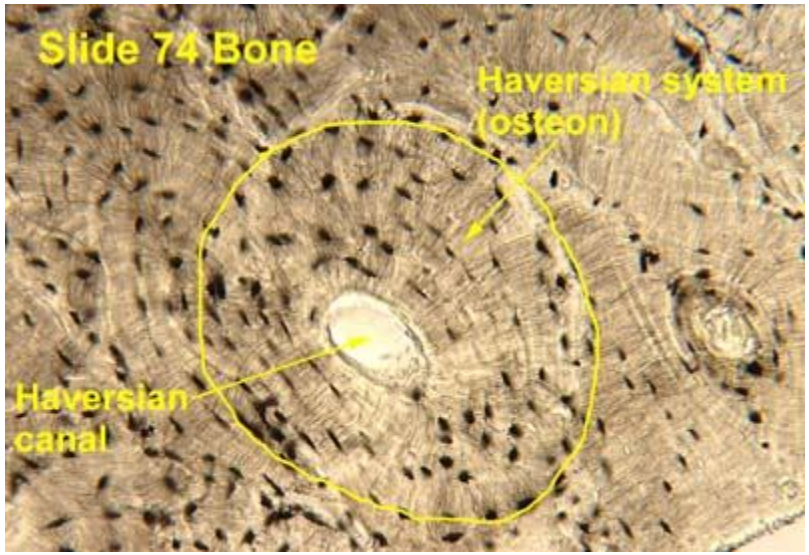

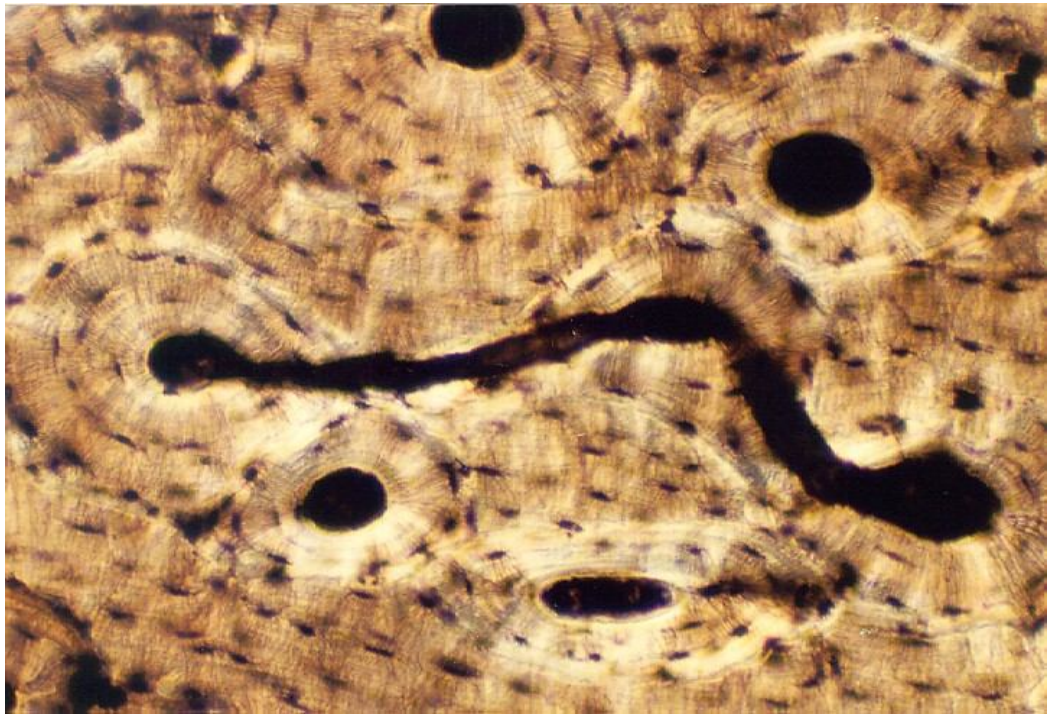

Multiple Osteons

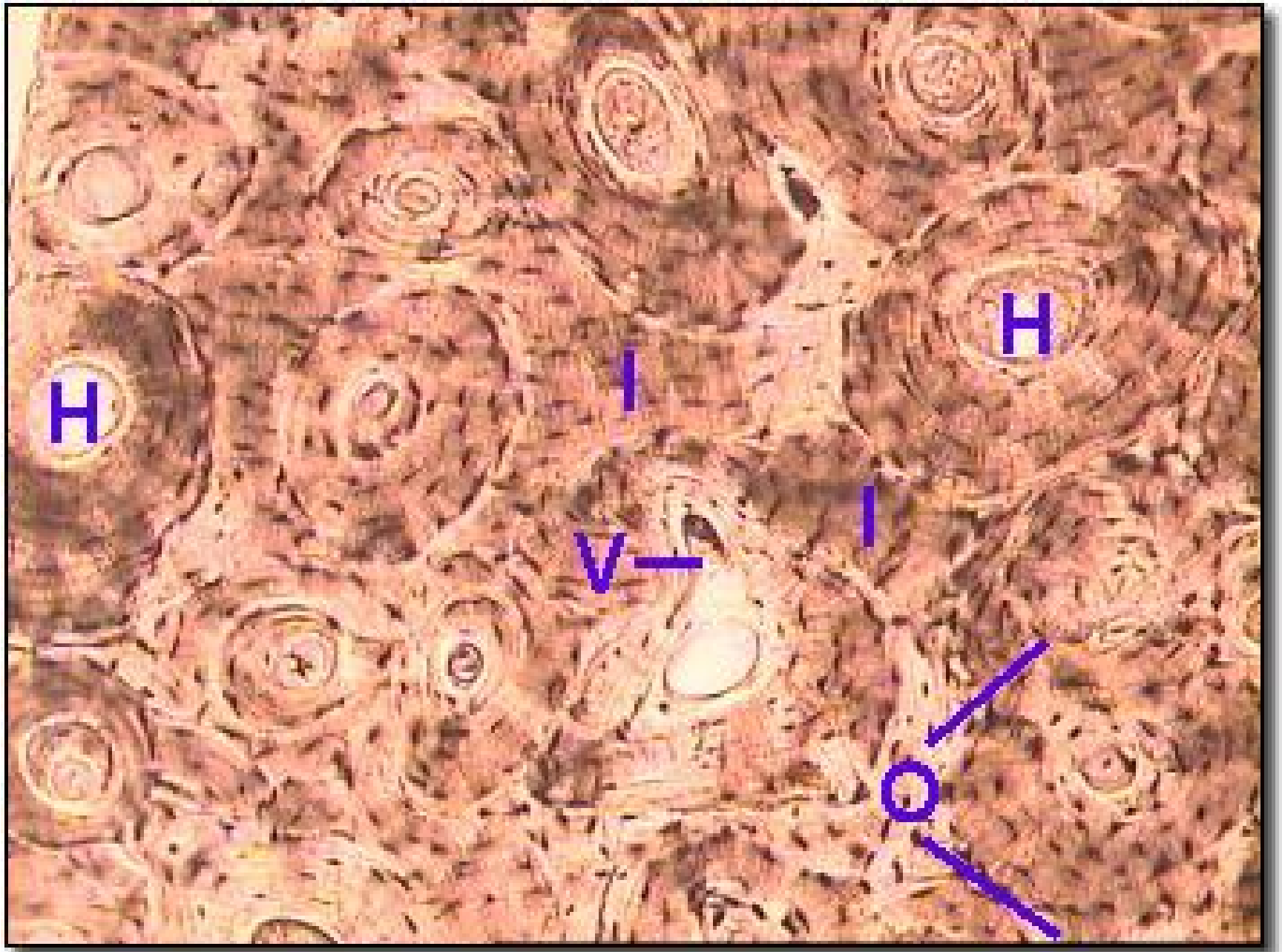

An Osteocyte

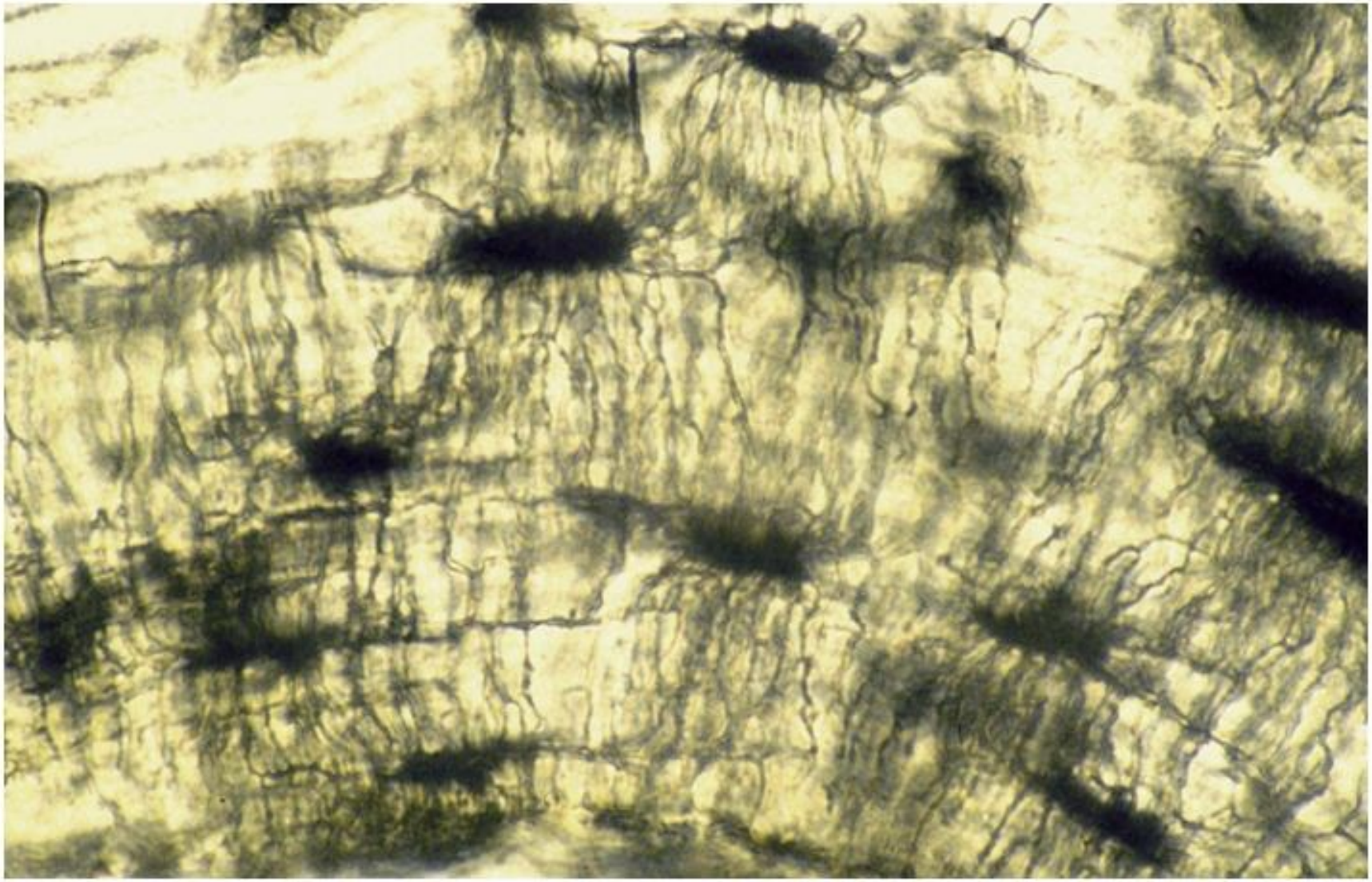

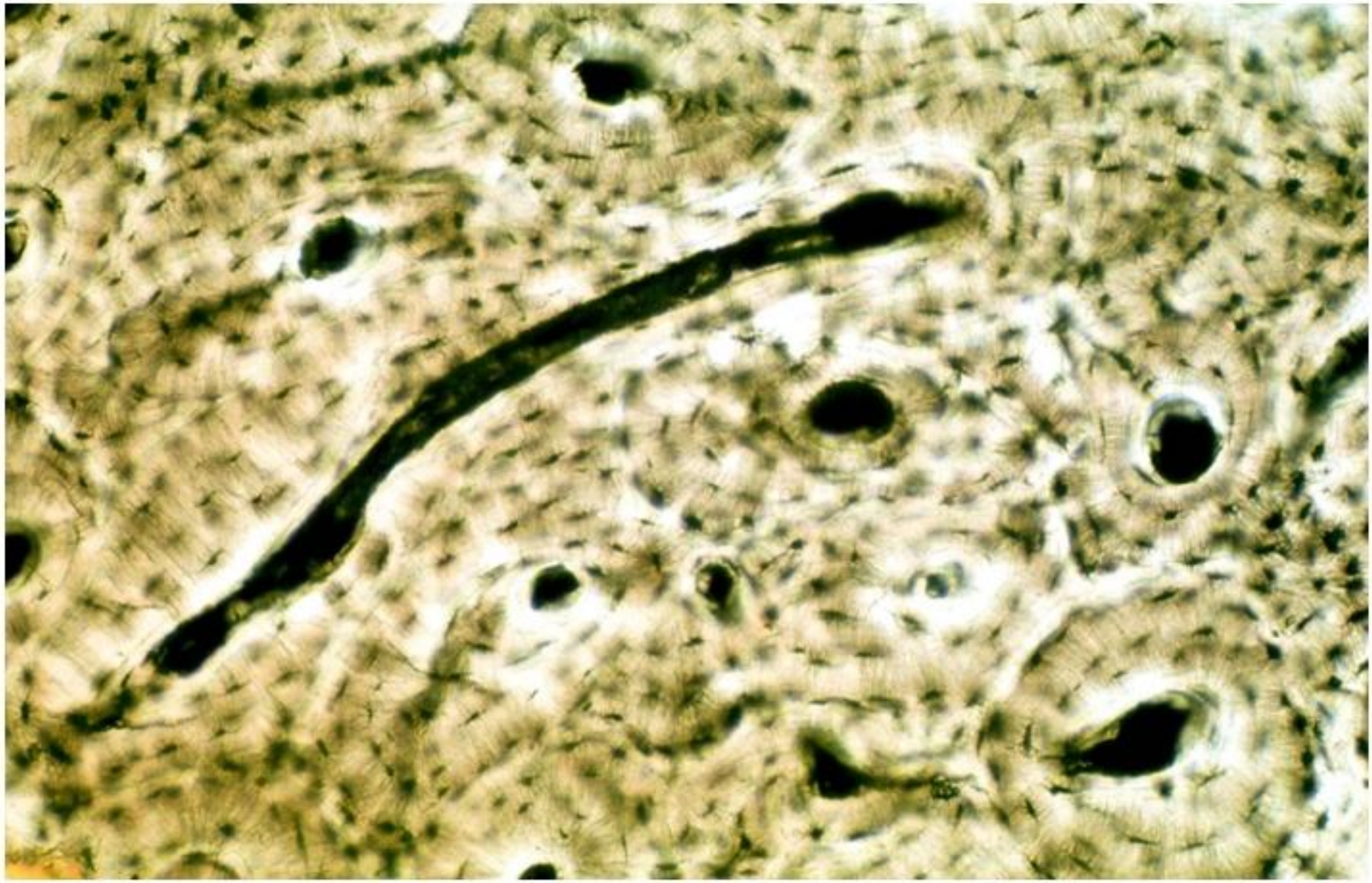

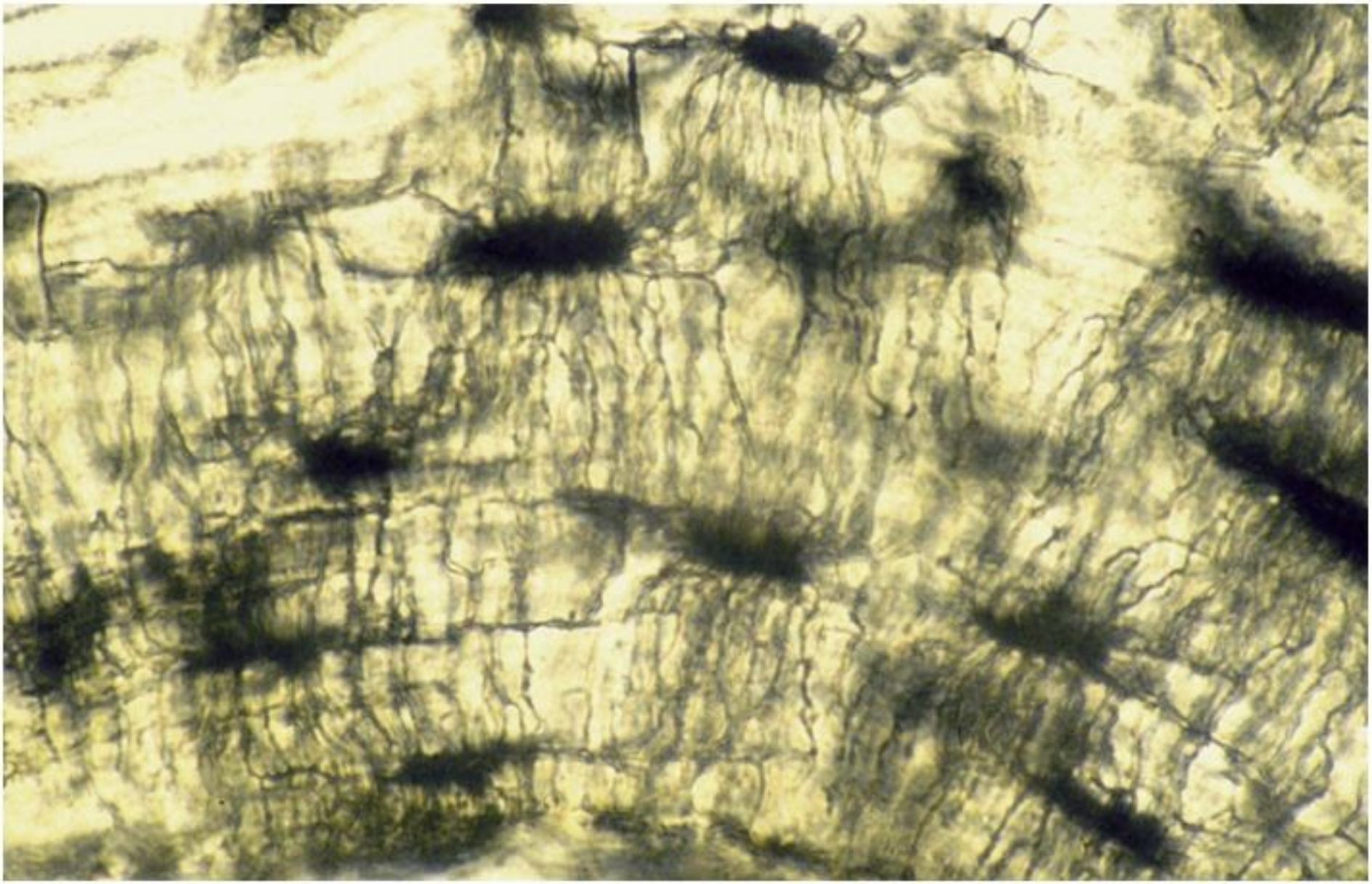

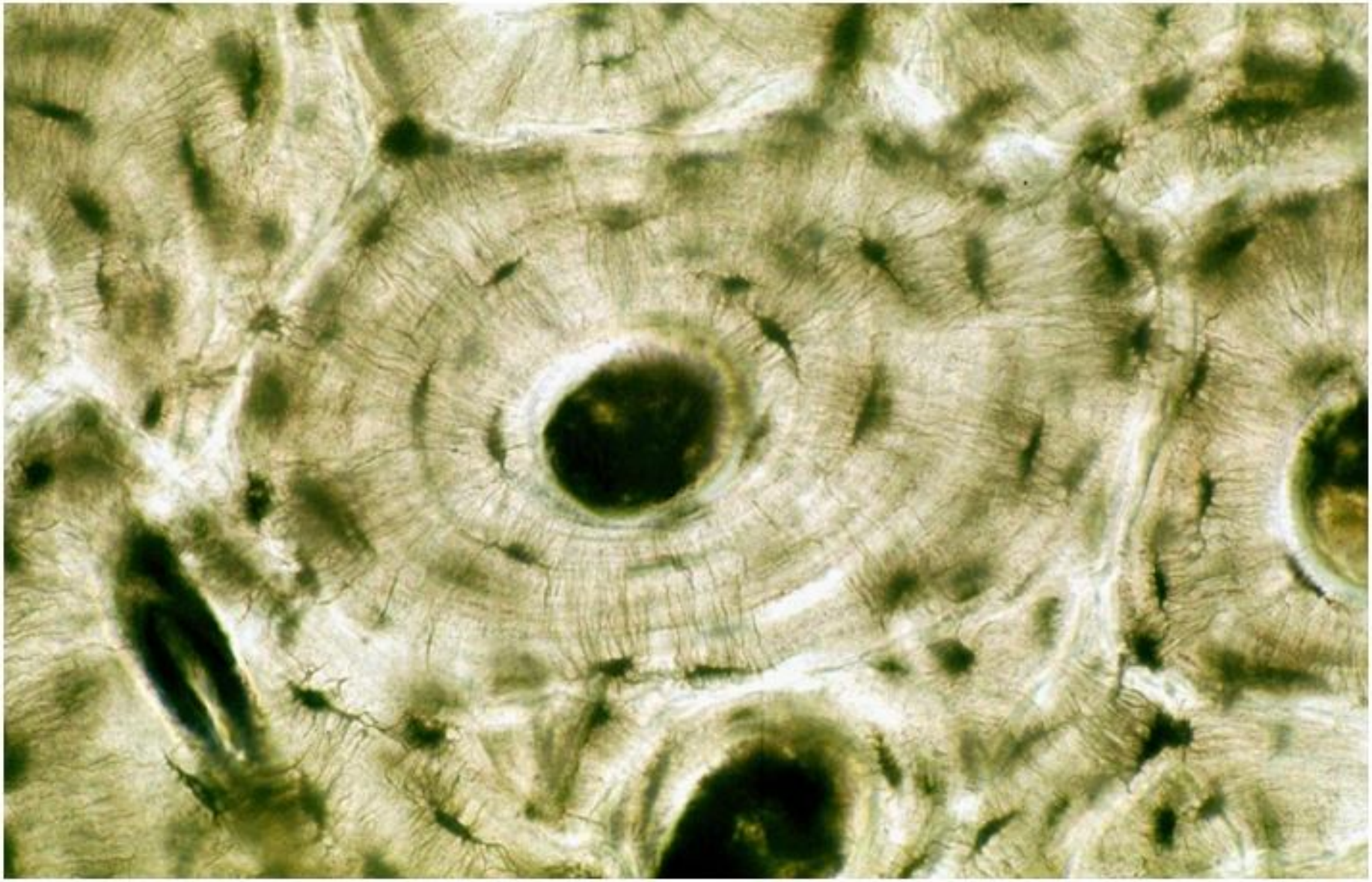



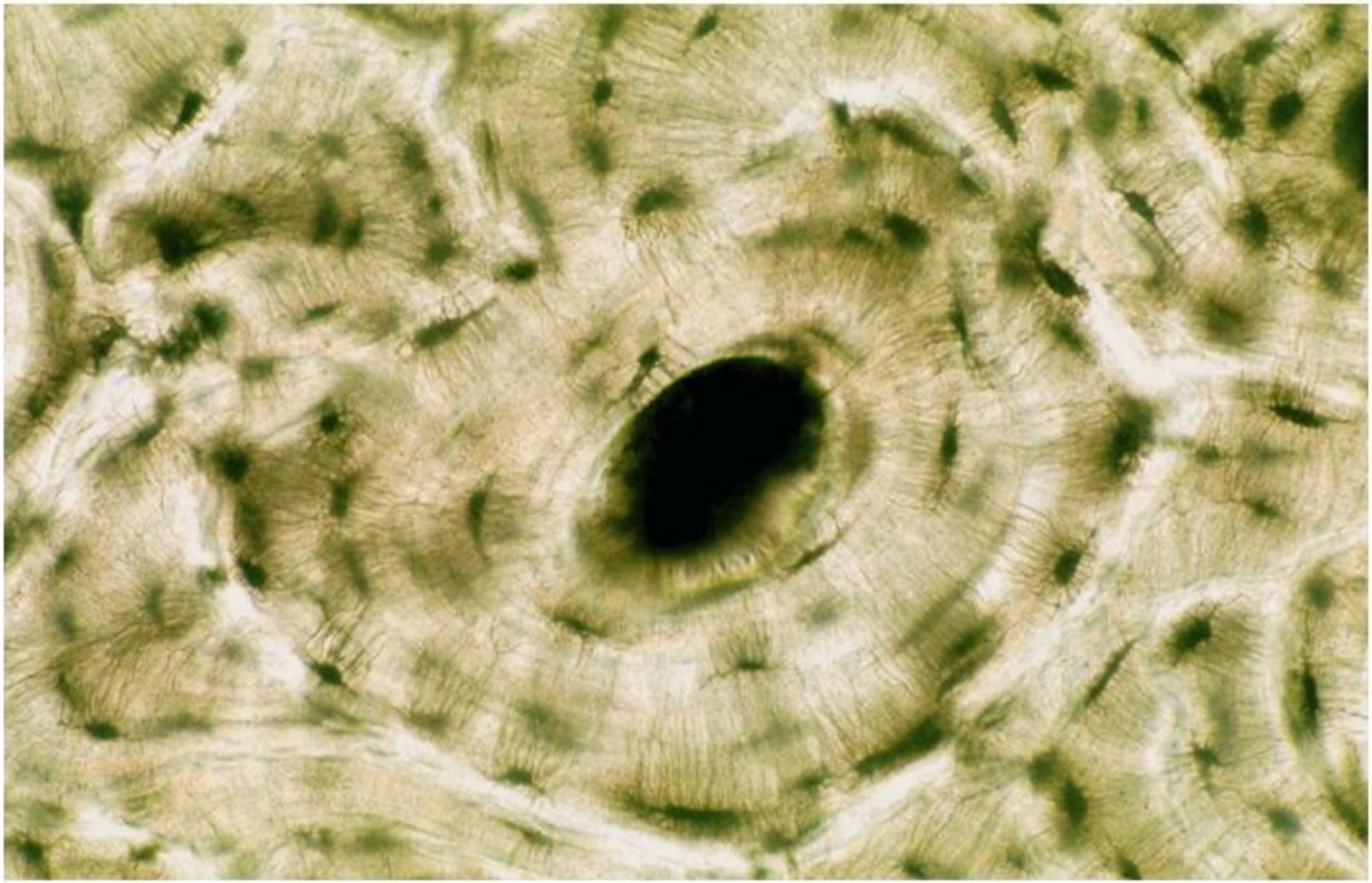

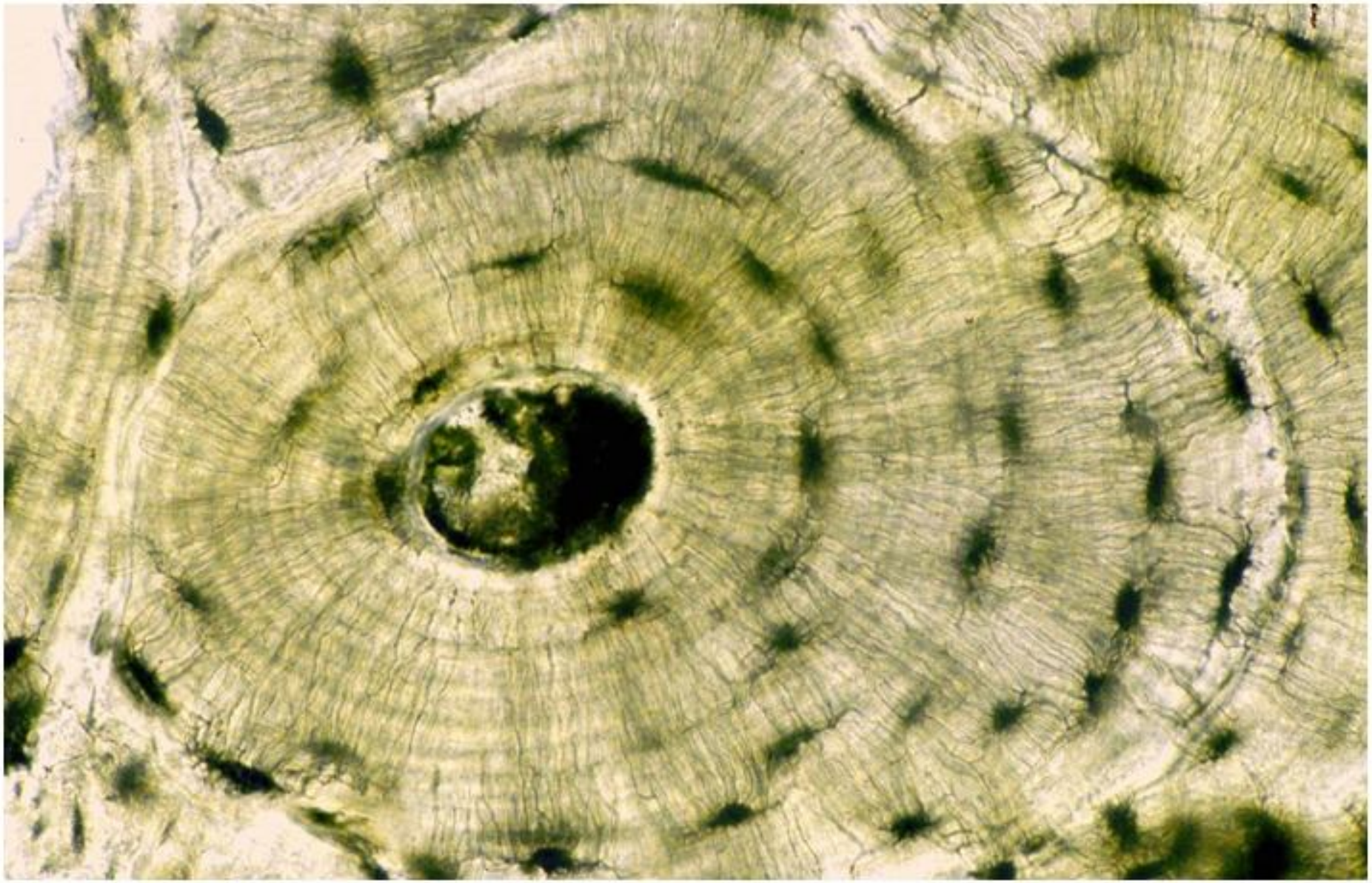

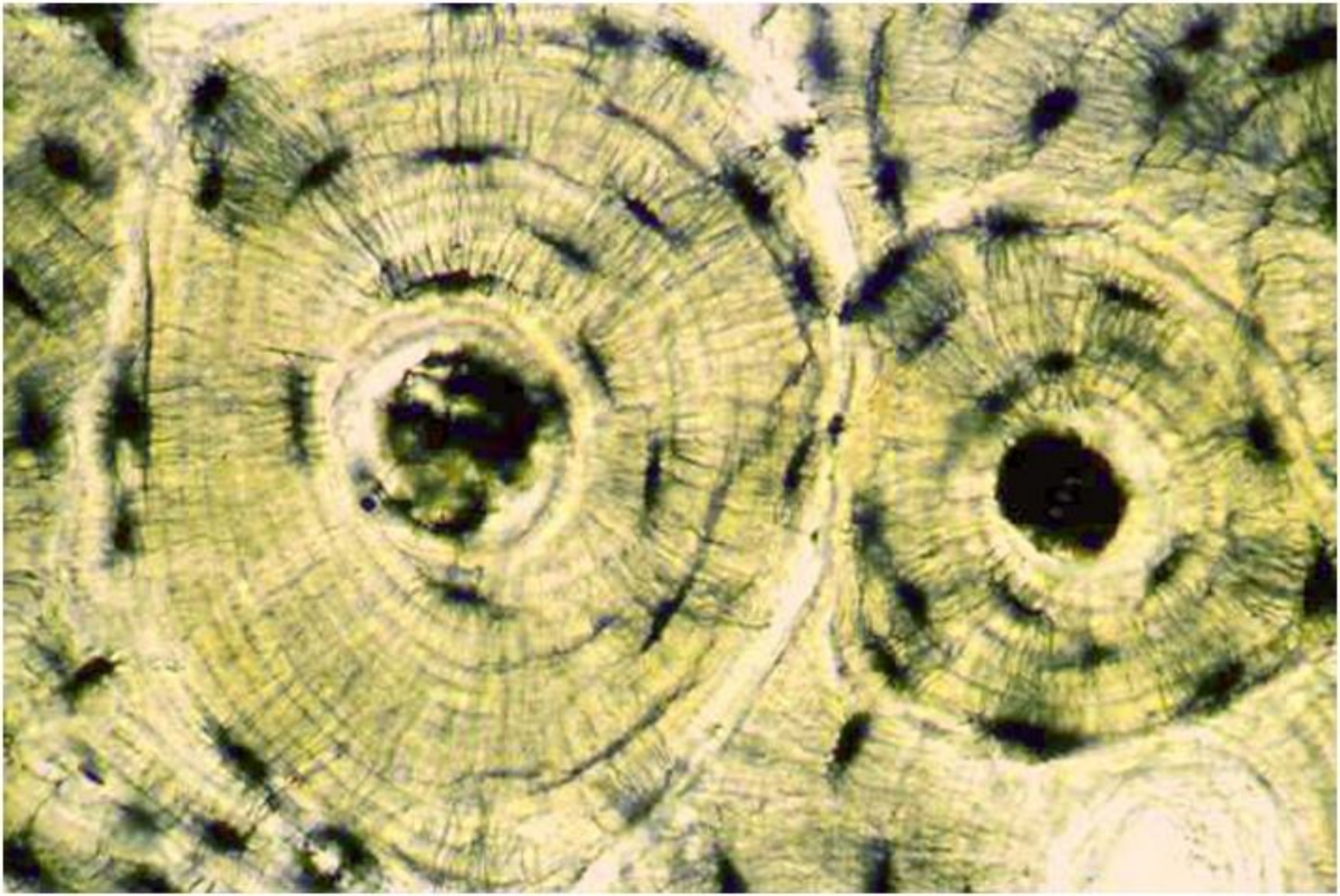

Cancellous or Spongy Bone

- Slender bony trabeculae that branch and anastomose with one another.
- Enclose irregular marrow spaces containing blood vessels and haemopoietic tissue that give rise to new blood vessels.
- They receive nutrition from blood vessels in the bone marrow

Examples of Cancellous bone

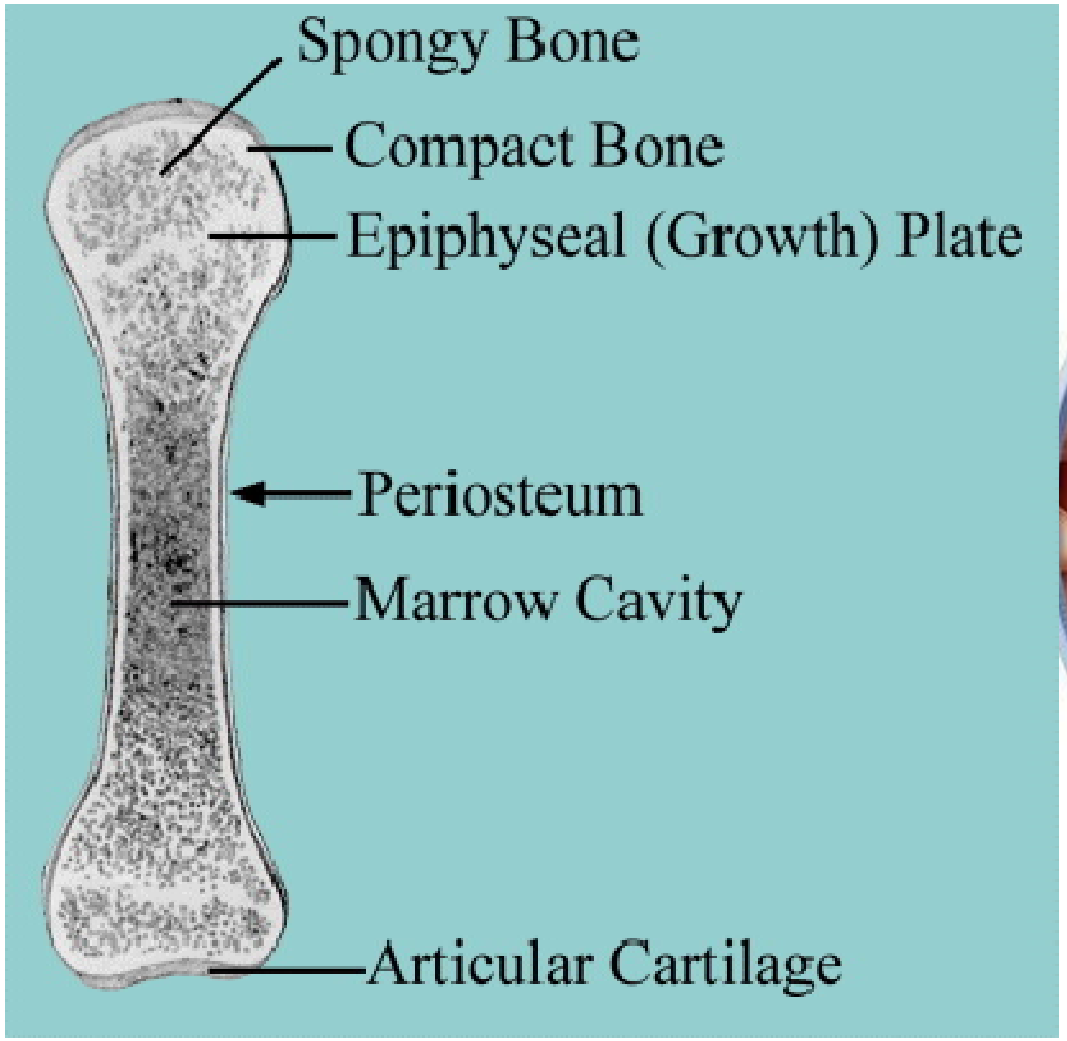

Cancellous Bone

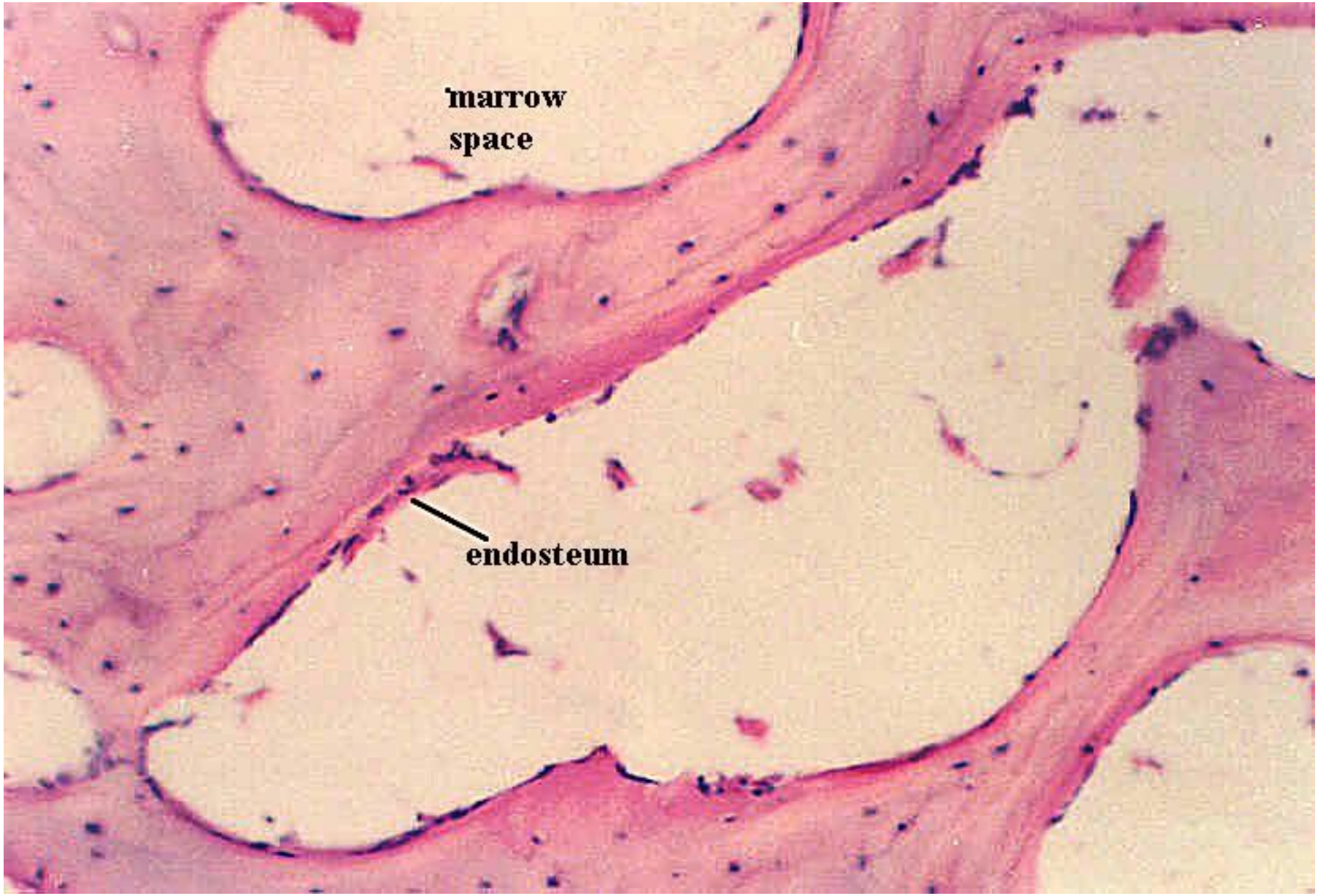

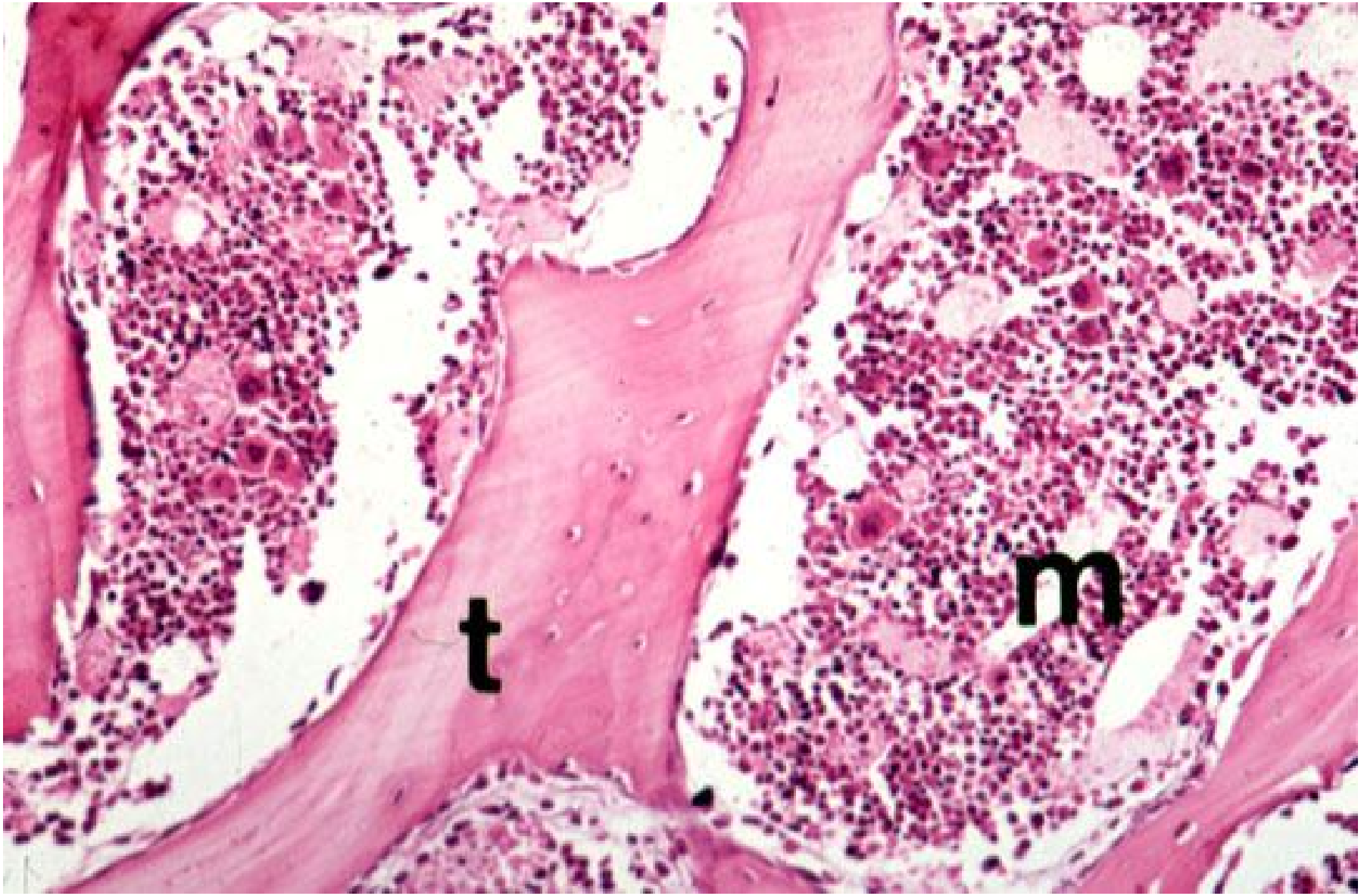
t
m

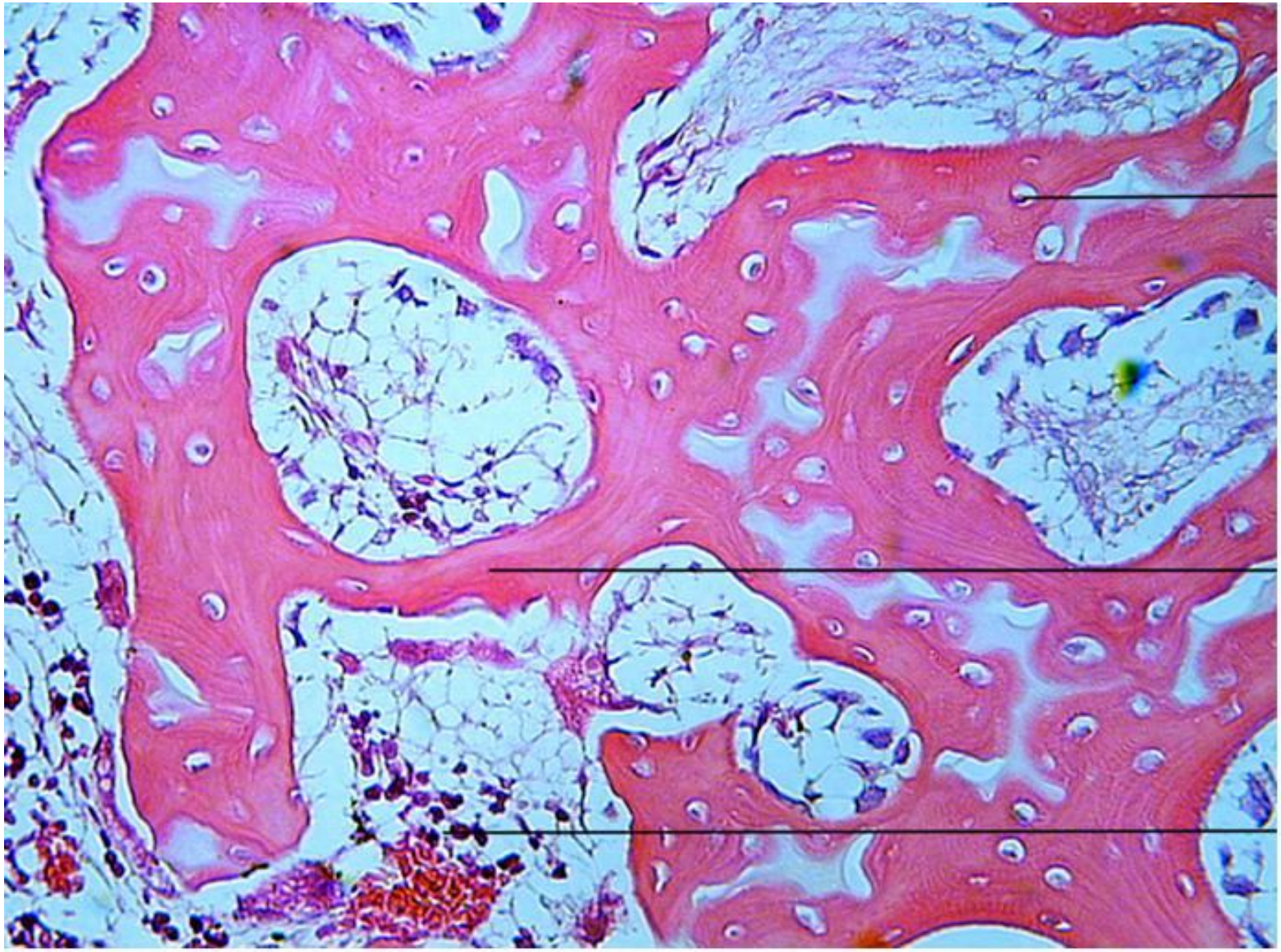

Cancellous (Spongy) Bone (400x)

Spongy Bone

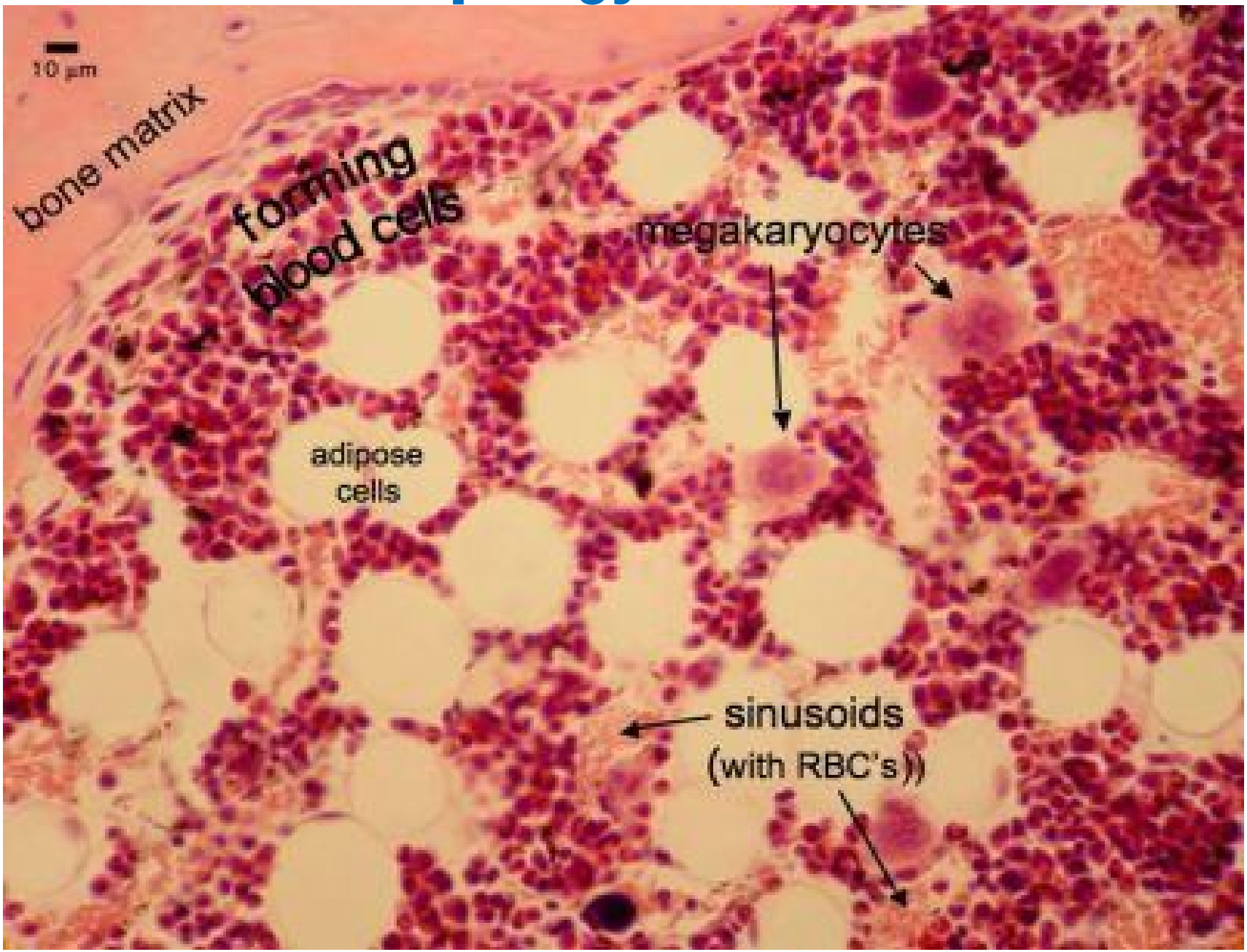
10 µm
bone matrix
forming blood cells
megakaryocytes
adipose cells
sinusoids (with RBC's))

Important facts

VITAMINS

- Vit D- absorption of Ca from small intestine
- Vit C: Collagen synthesis
- Vit A-Ossification

HORMONES

- Parathyroid Hormone: activates osteoclasts to resorb bone , therefore increased Ca in inblood.
- Calcitonin: inhibits bone resorption by osteoclasts. Decreased Ca in blood

MCQ

Periosteum is absent over the following EXCEPT

1. Articular surface of bone
2. Sesamoid bone
3. Site of attachment of tendons and ligaments to the bone
4. Shaft of long bones

MCQ

Osteocytes may be identified by the presence of

1. Many Nuclei
2. Lacuna around the cell
3. Lysosomes
4. Ingested particles

MCQ

Alkaline phosphatase activity can be demonstrated in

1. Osteoblasts
2. Osteocytes
3. Osteoclasts
4. Osteoprogenitor cells

MCQ

Spongy bone can be identified histologically by the presence of

1. Haversian canal and concentric bony lamellae
2. Bony trabeculae and marrow cavity
3. Interstitial Lamellae
4. Volkmann's Canal

MCQ

The vitamin necessary for the absorption of calcium from small intestine is

1. A
2. B
3. C
4. D

Identify the given slide

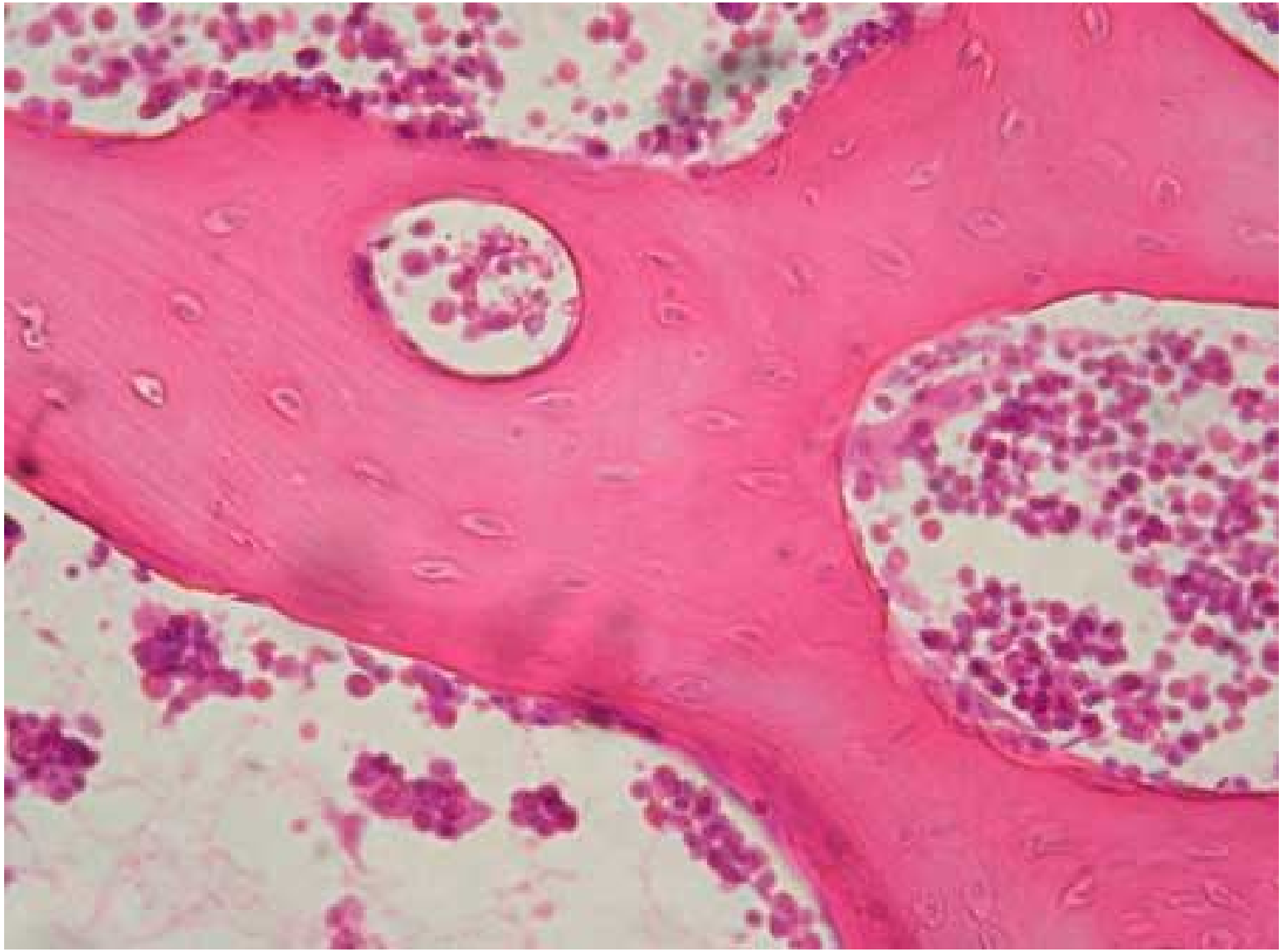

Identify the slide

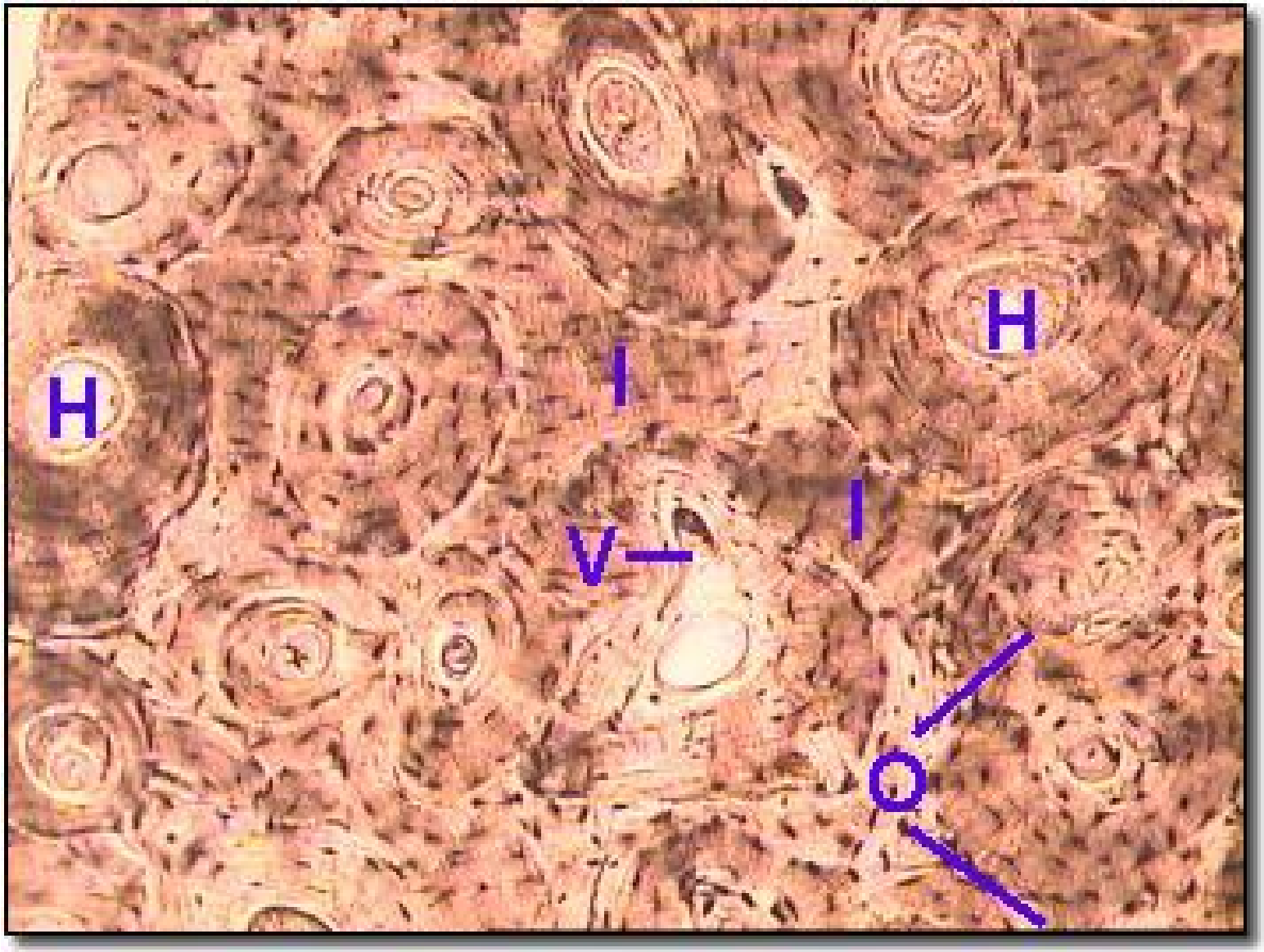

Fill in the Blank

- **The Hardness and rigidity of bone is due to the presence of .....**

Fill in the Blank

- **Newly formed unmineralized matrix is called**

.....

Fill in the Blank

- The thin vascular membrane that lines the marrow cavity is .....

Fill in the Blank

- Osteoclasts are found in specialized depressions on the surface of the bone called .....

Osteon

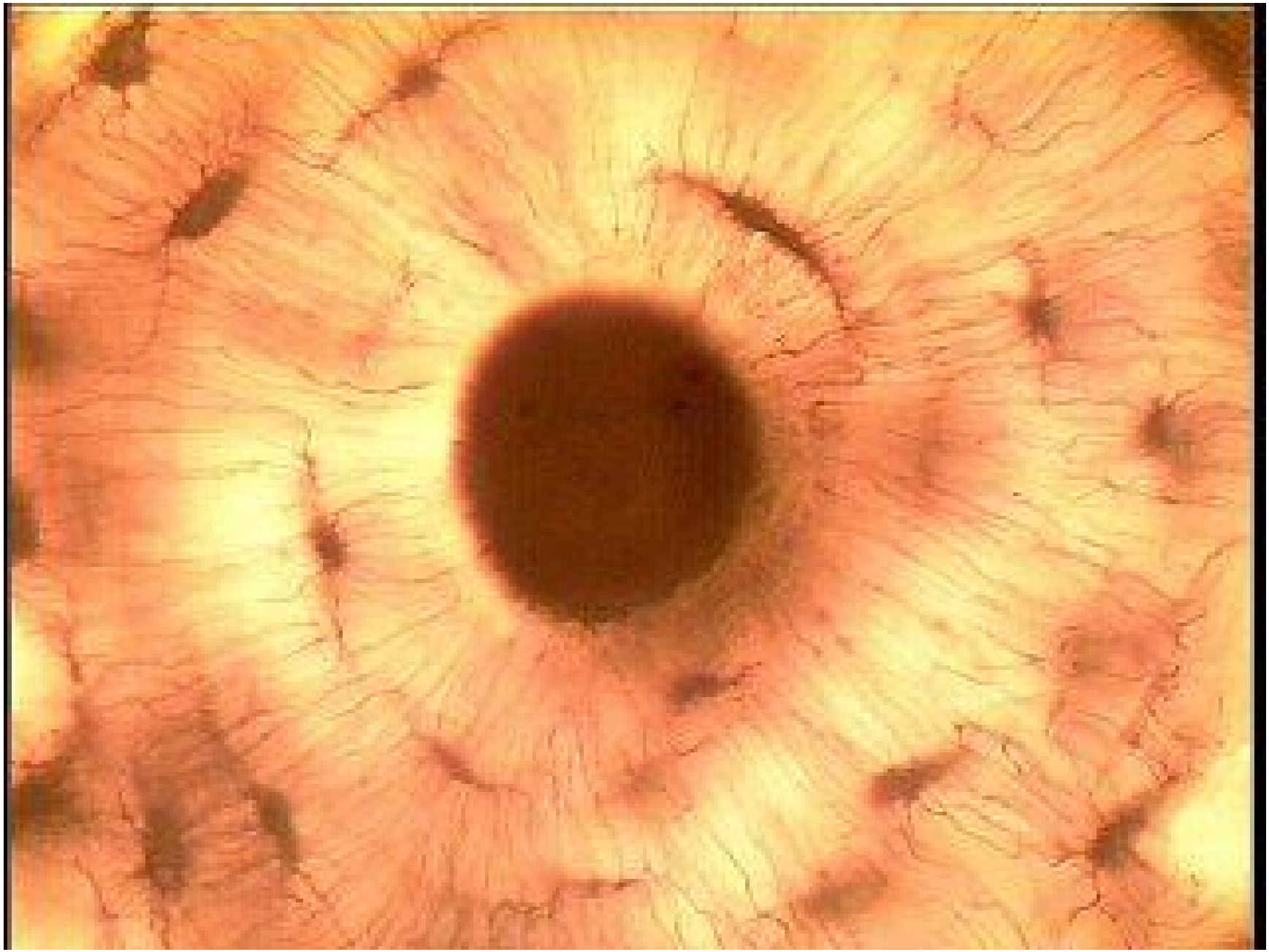

Identification Points

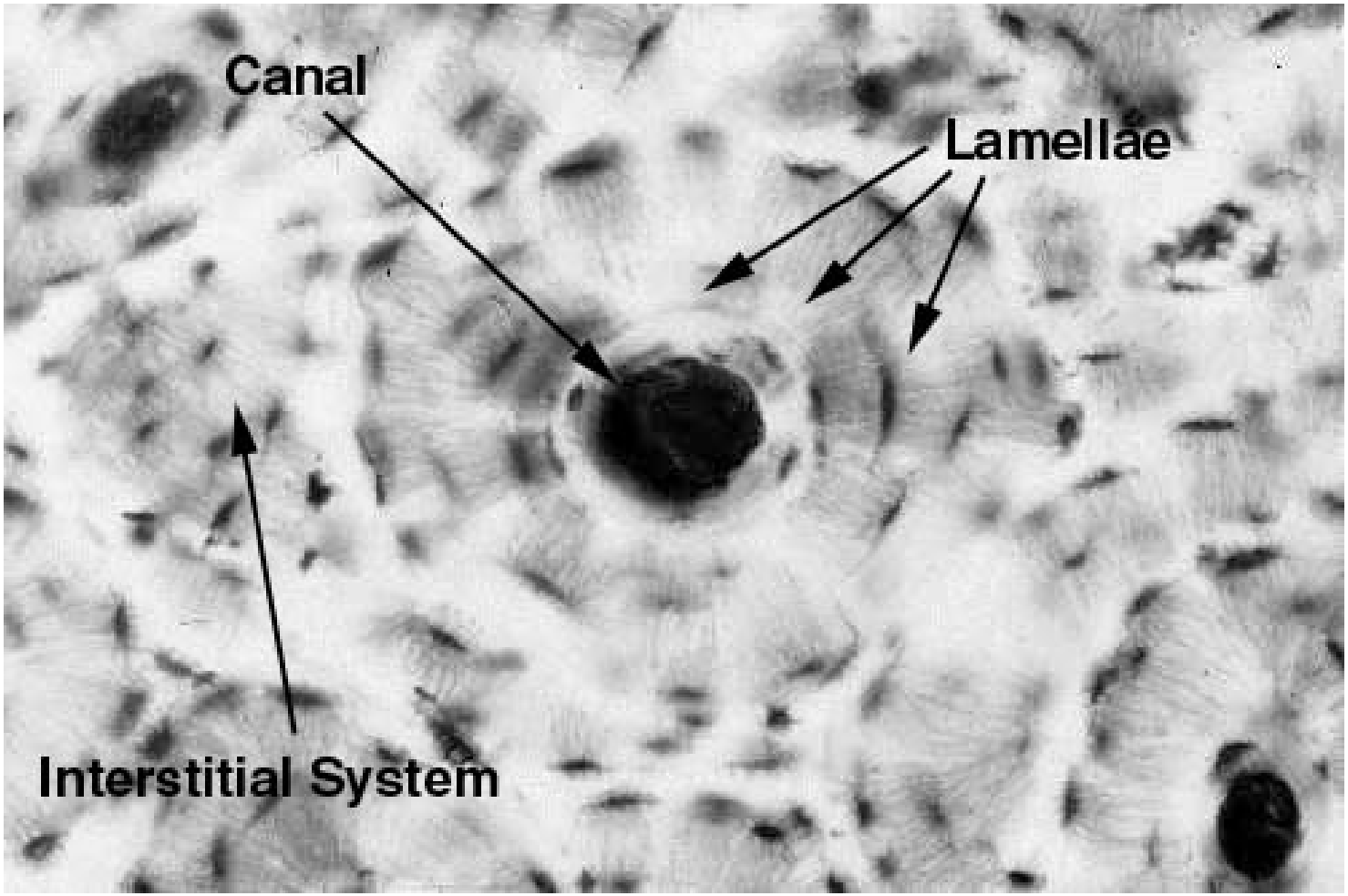

- Osteons
- Haversian Canal
- Different types of Lamelle