

# Parotid Region

[para=around, otic=ear]

Presented by :- Dr. Sushma Tomar  
Associate Professor  
Department of Anatomy

# Boundaries of Parotid Region

## Anterior-

- Anterior border of Masseter.

## Above-

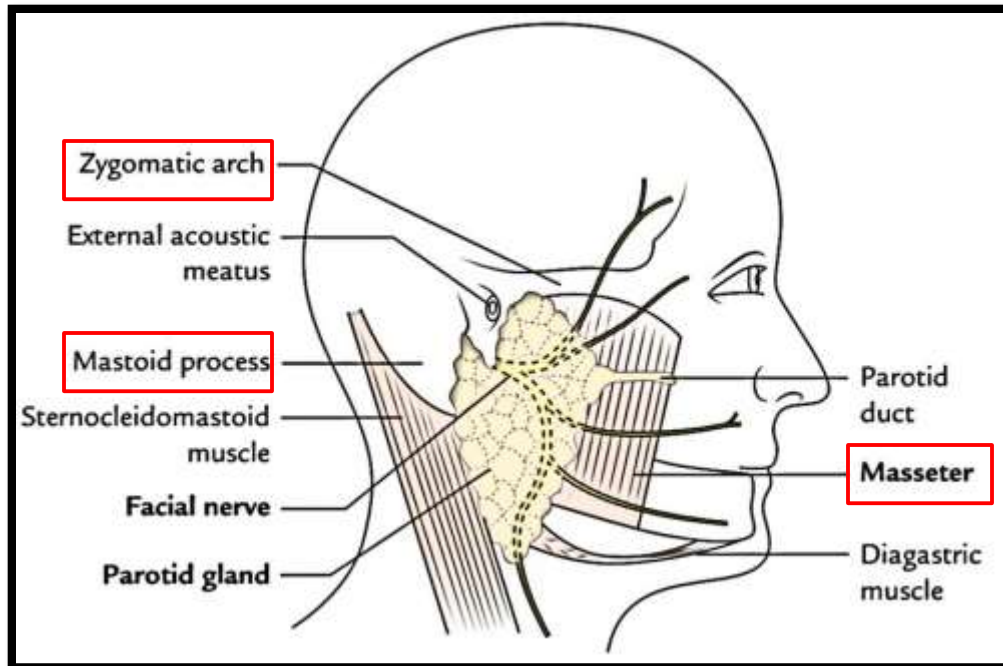
- Zygomatic arch.

## Posterior-

Mastoid process.

## Below-

- An imaginary line joining the angle of mandible with mastoid process.



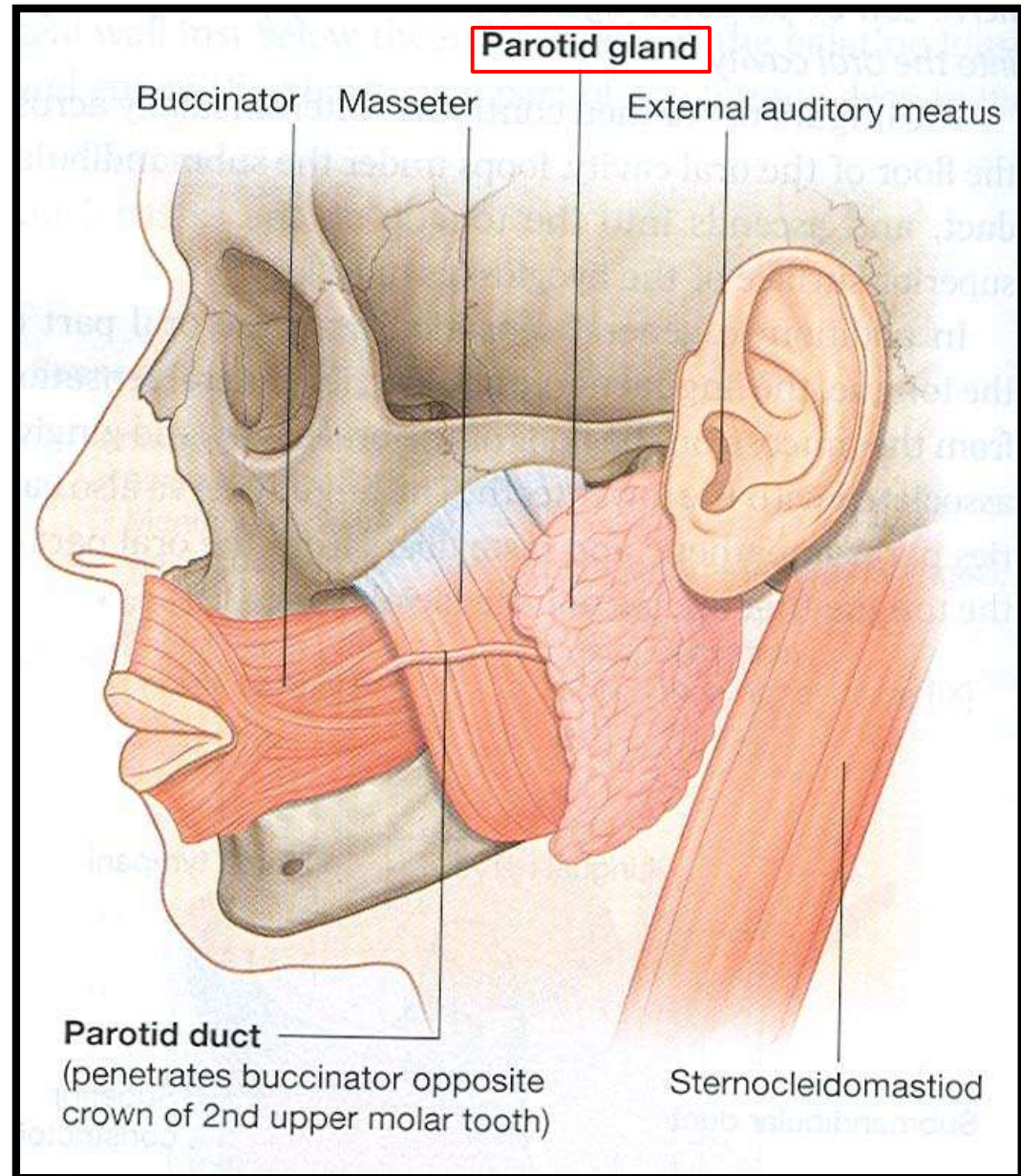
# Parotid Gland

# Parotid Gland

- It is the largest salivary gland.

## Location-

- Retromandibular fossa (posterior to ramus of mandible).



# Boundaries of Parotid Bed

## Anterior-

- Posterior border of ramus of mandible.

## Posterior-

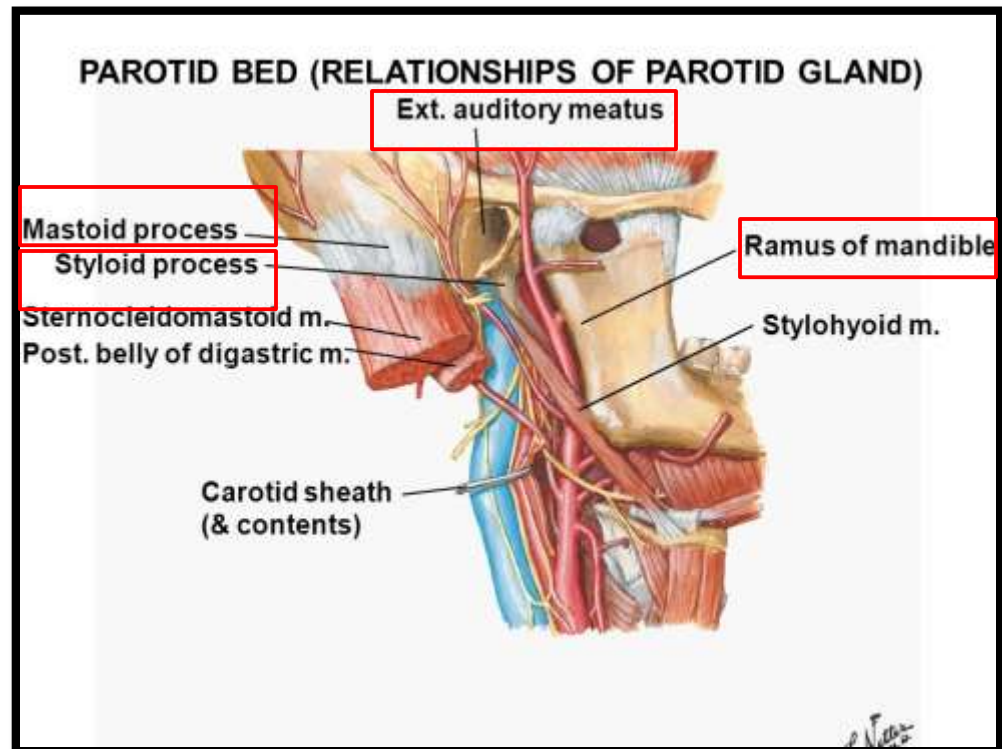
- Mastoid process.

## Above-

- External acoustic meatus.
- Posterior part of Temporomandibular joint.

## Medial-

- Styloid process.



# Extension of Parotid Gland

## Above-

- To the External auditory meatus.

## Below-

- To the upper part of carotid triangle.

## Medial-

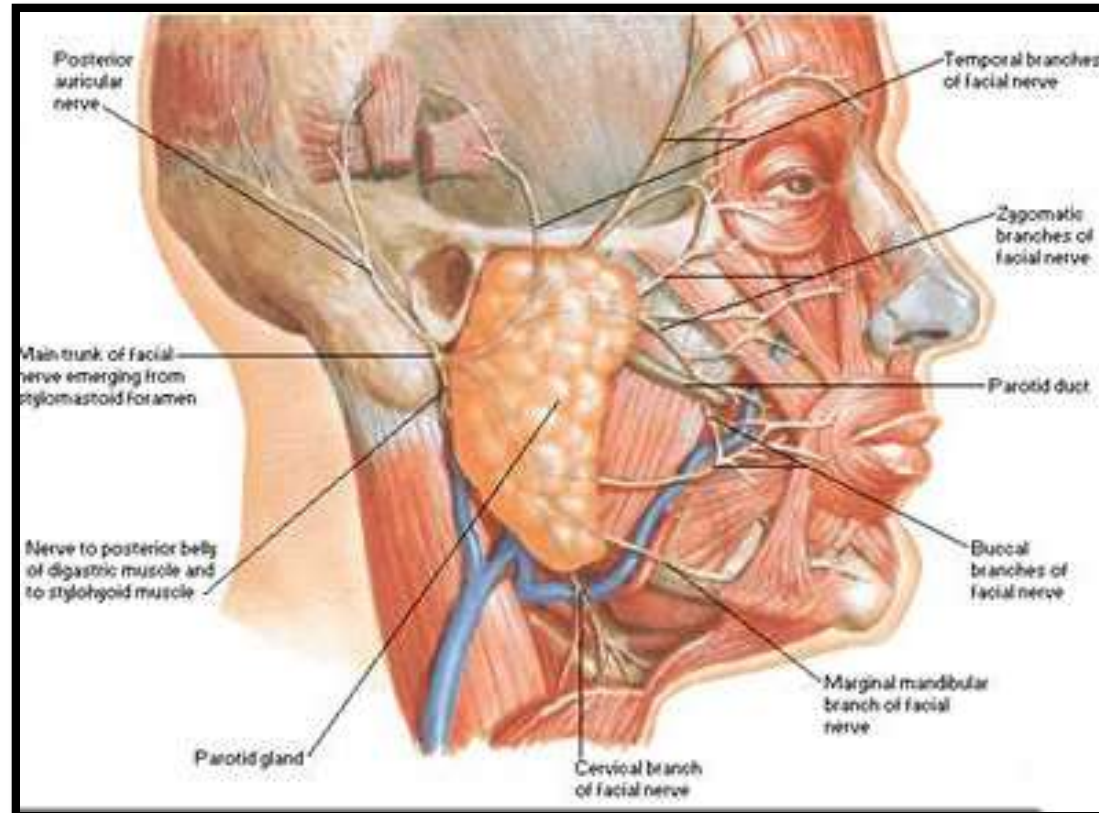
- To the styloid process.

## Anterior-

- Extends over Masseter.

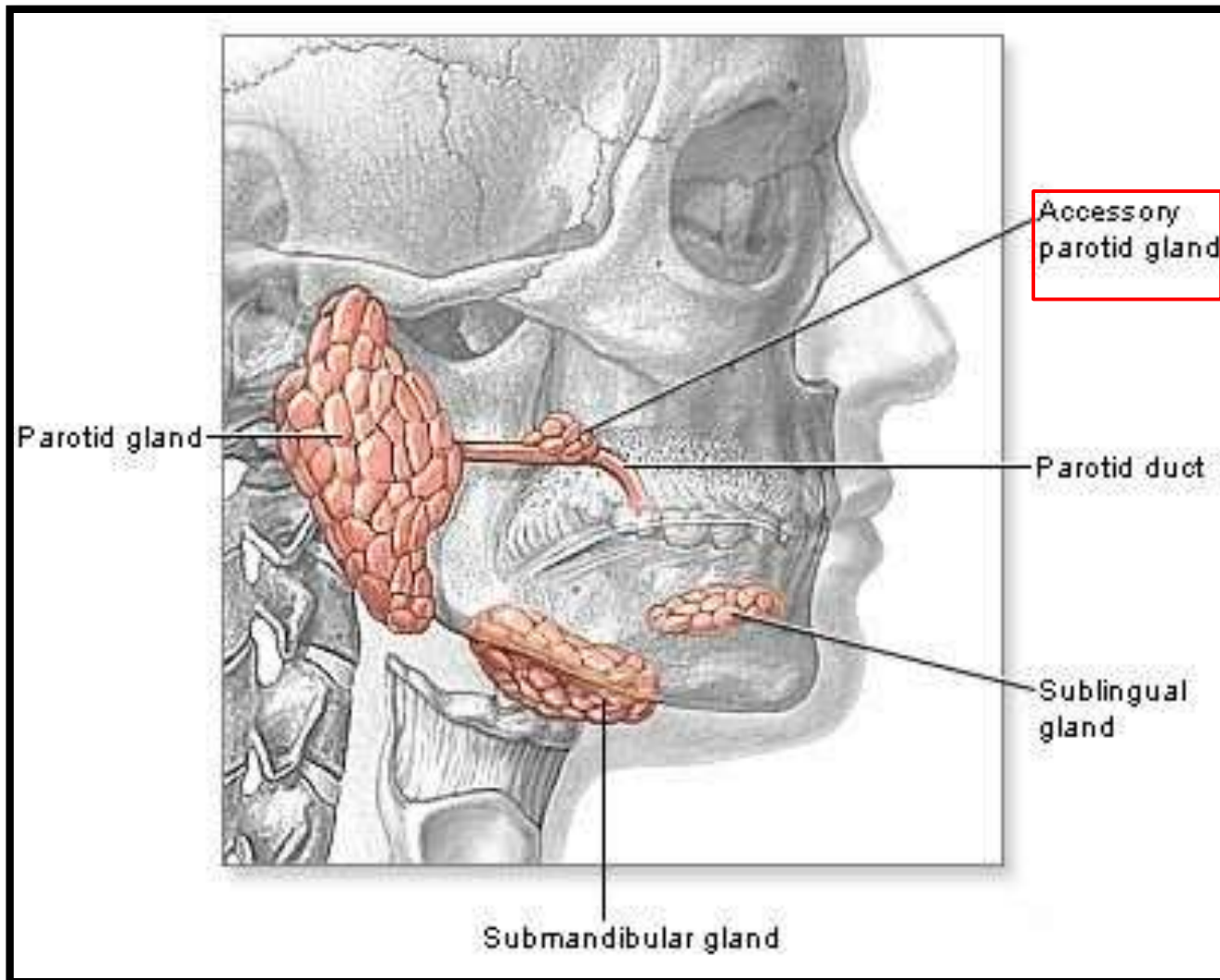
## Posterior-

- Overlaps Sternocleidomastoid muscle.

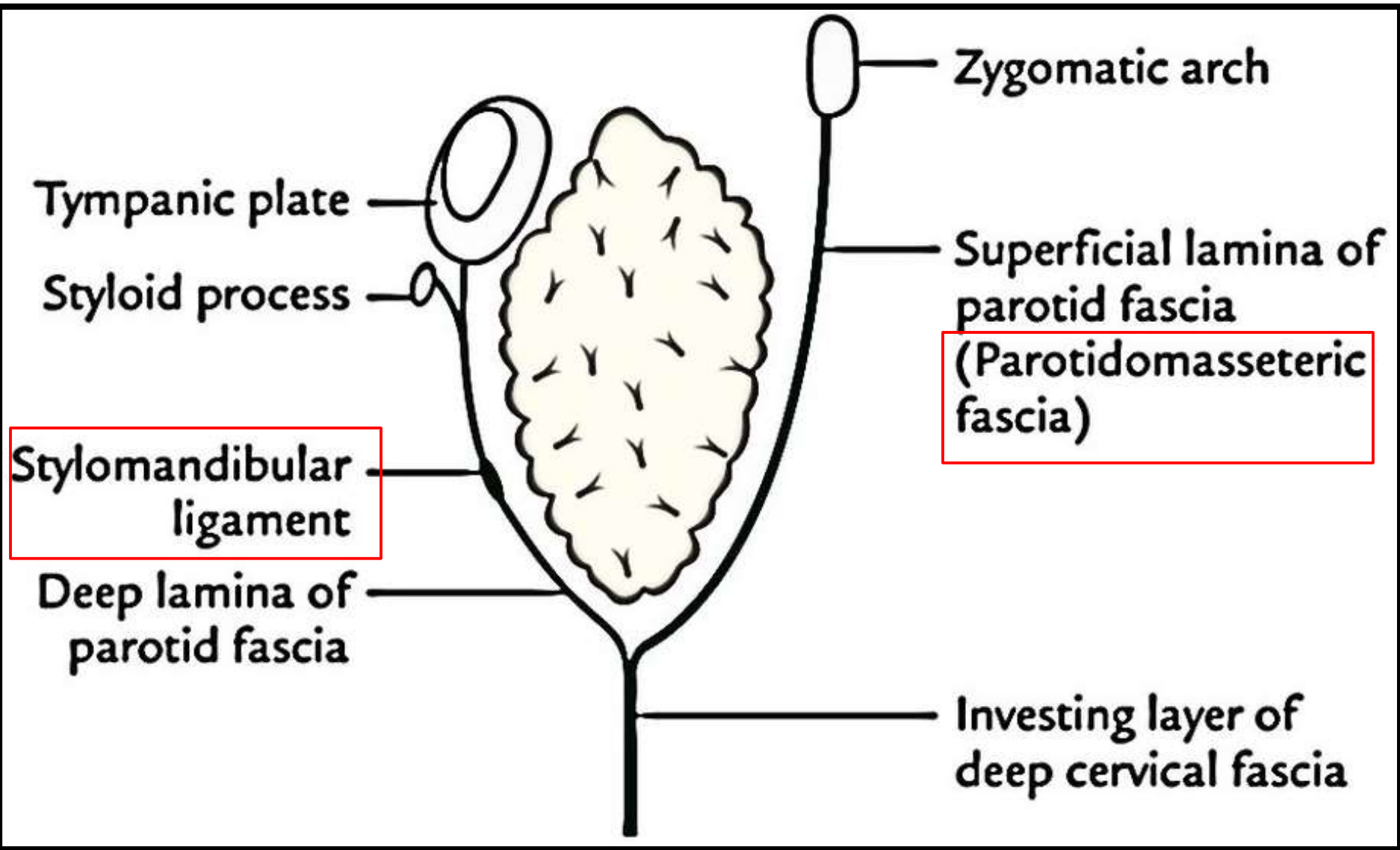


# Accessory Parotid Gland

- A part of the forward extension of parotid gland is detached from the rest of the gland and is known as **accessory parotid gland**.



# Capsule of Parotid Gland





# Presenting Parts

## Shape-

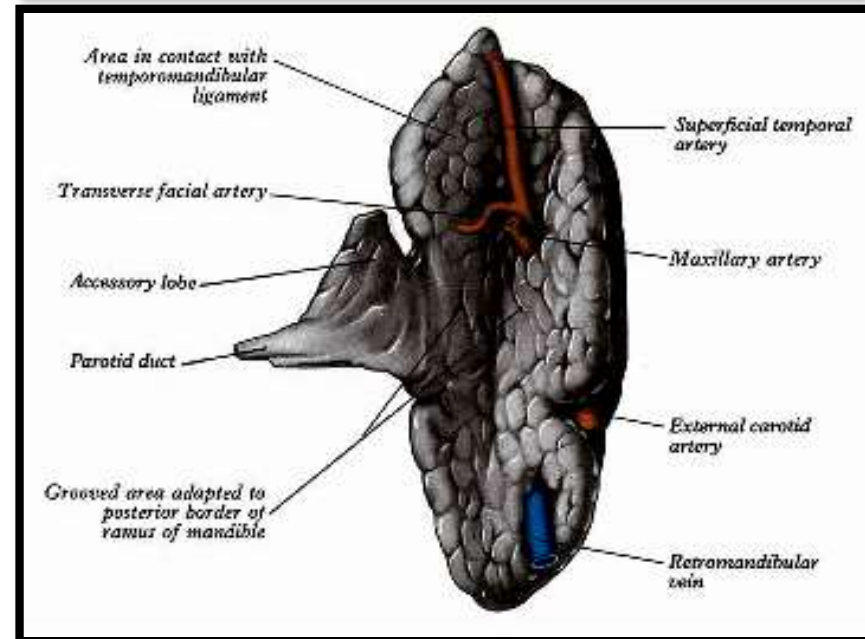
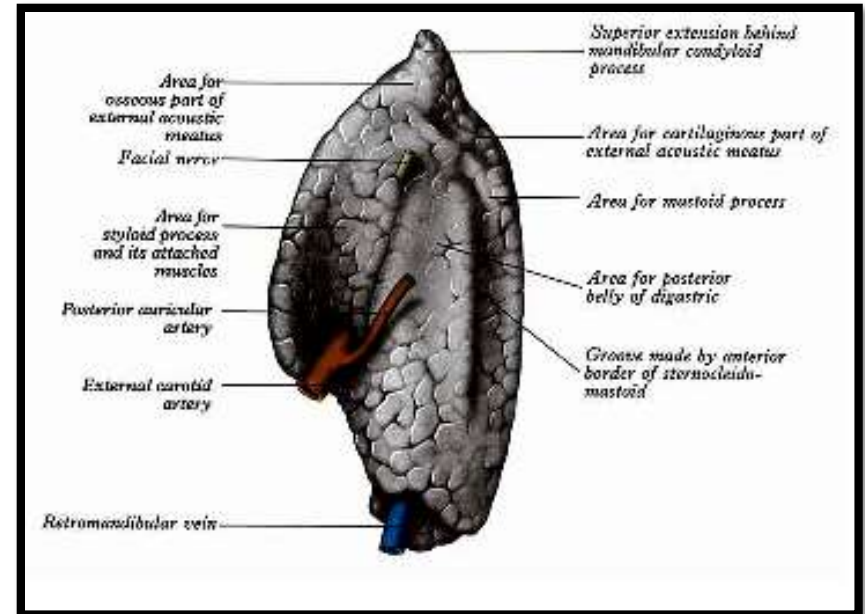
- Three – sided pyramid.
- Apex is directed downwards.

## Surfaces- 4

- Superior (Base)
- Superficial
- Anteromedial
- Posteromedial

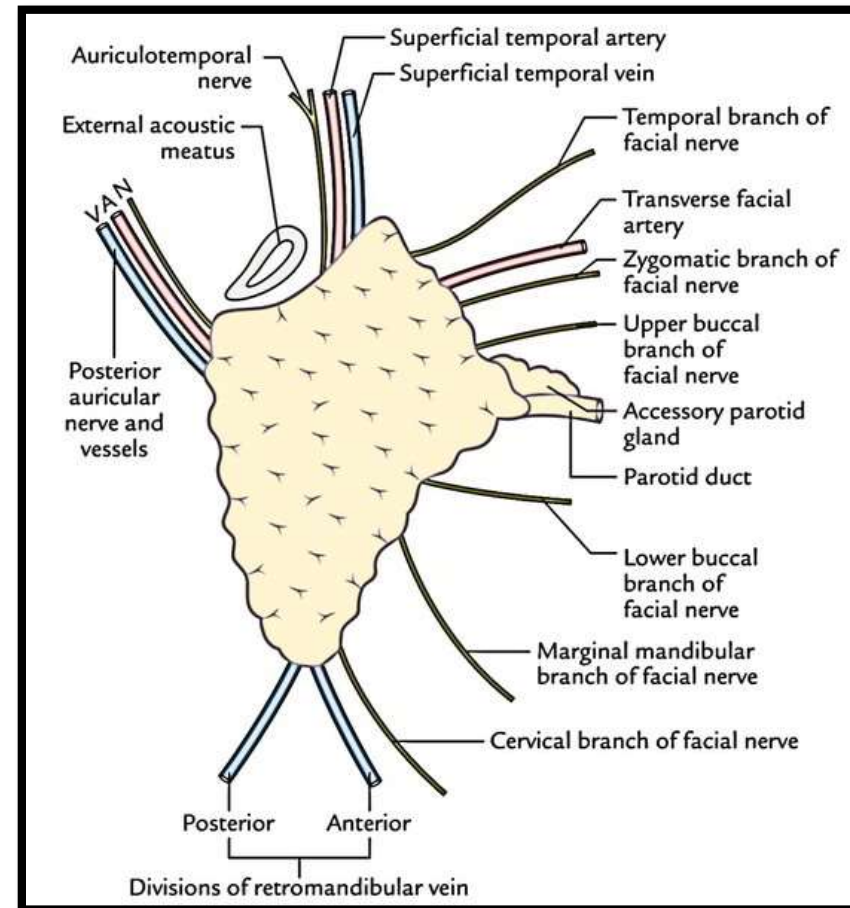
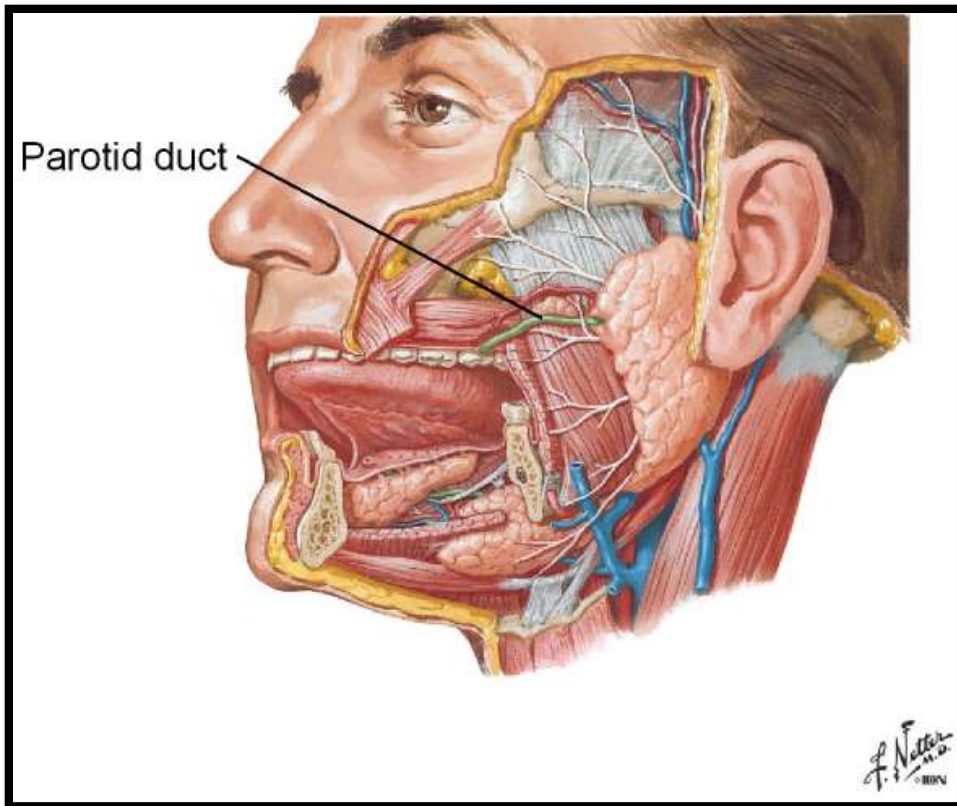
## Borders- 3

- Anterior
- Posterior
- Medial

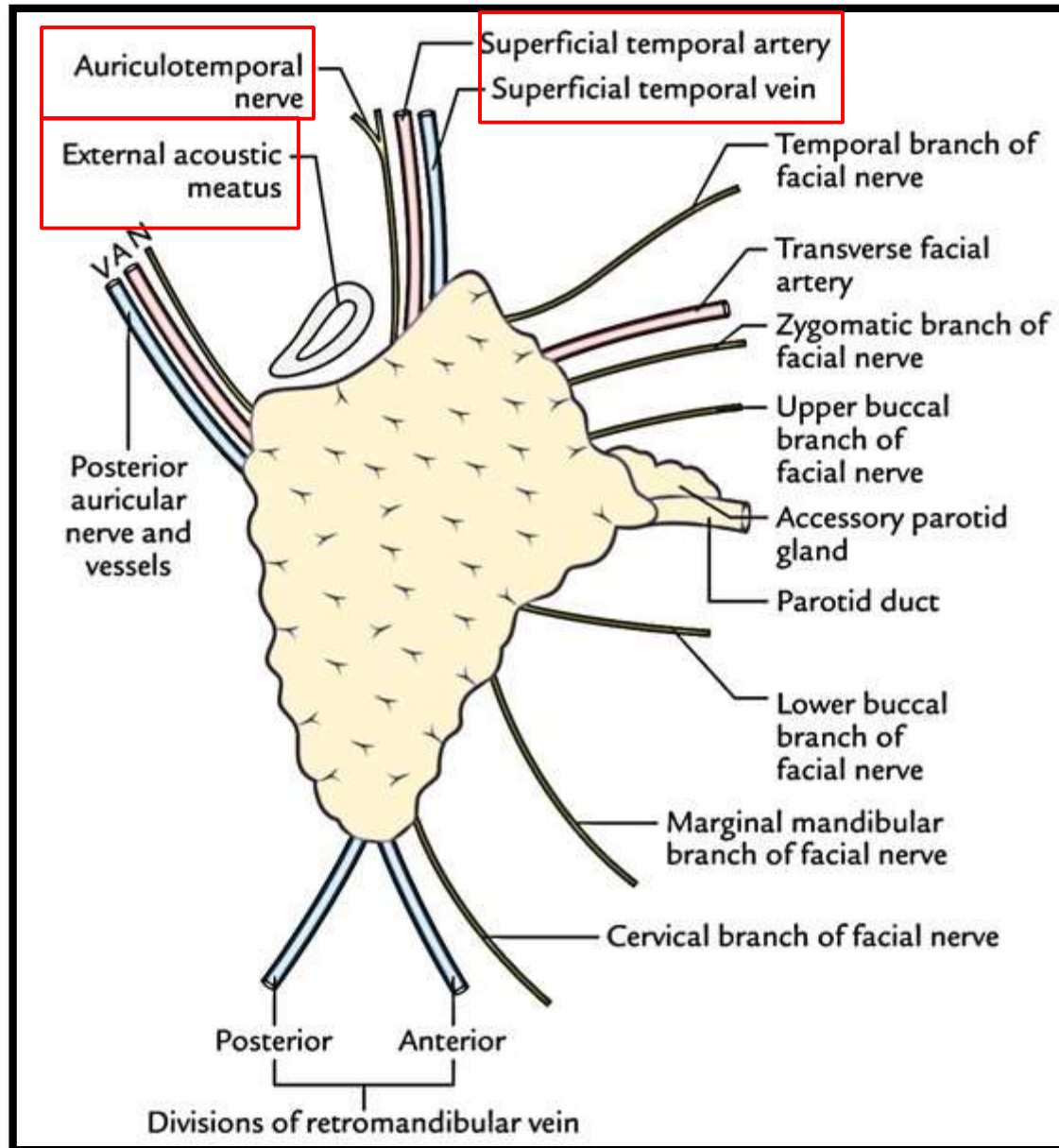


# Relations of Apex

- Apex overlaps the posterior belly of digastric muscle.



# Relations of Superior surface (Base)



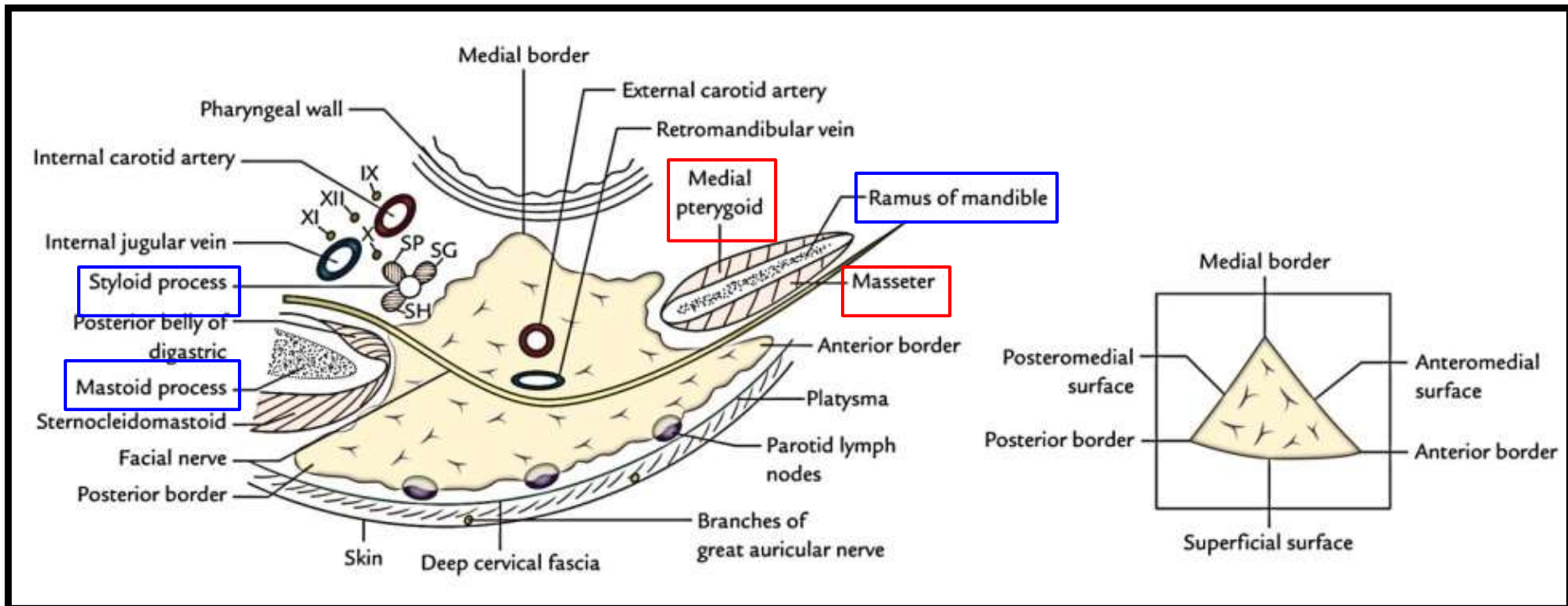
# Relations of Anteromedial and Posteromedial surfaces

## Anteromedial surface-

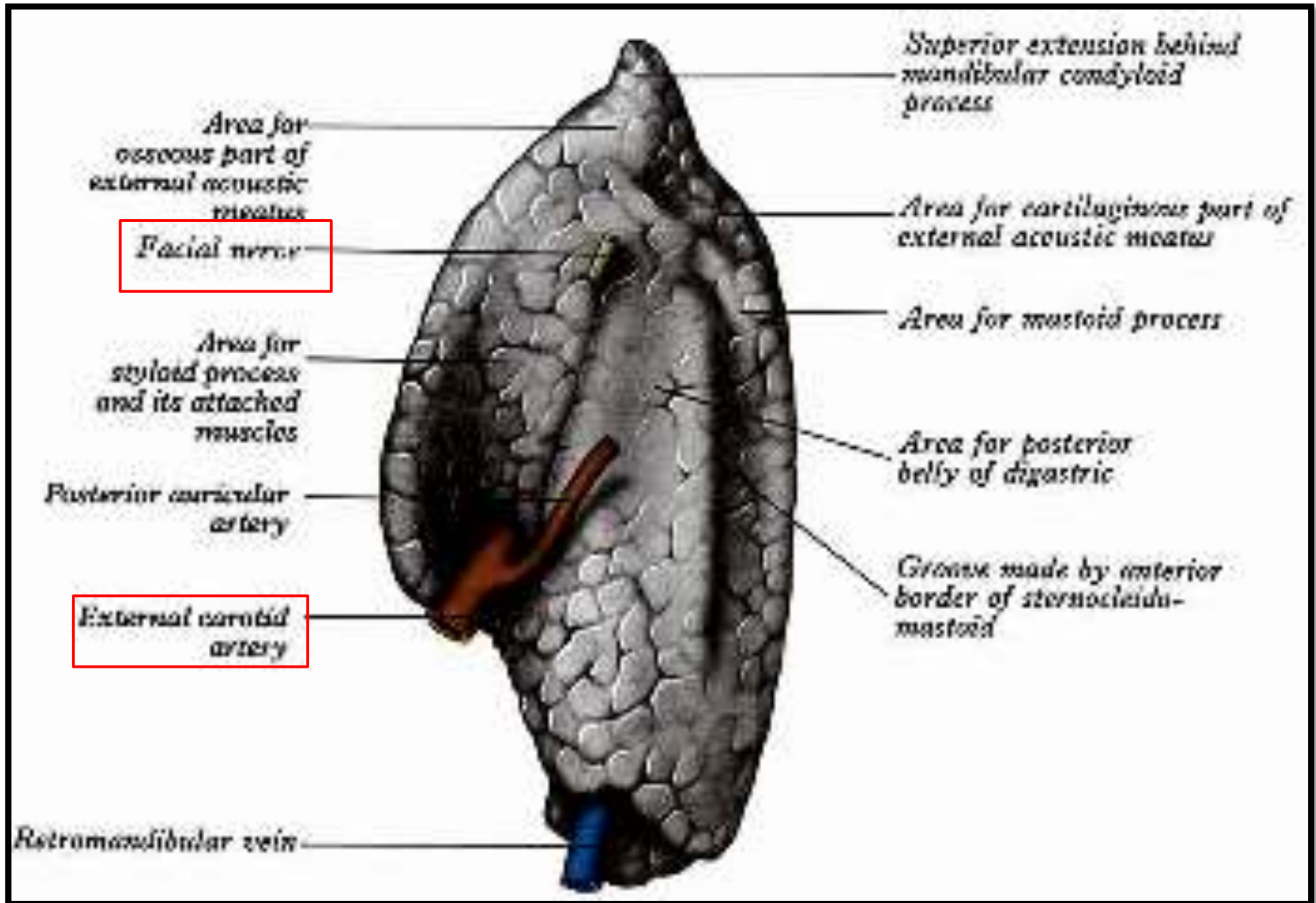
- Deeply grooved by posterior border of ramus of mandible.

## Posteromedial surface-

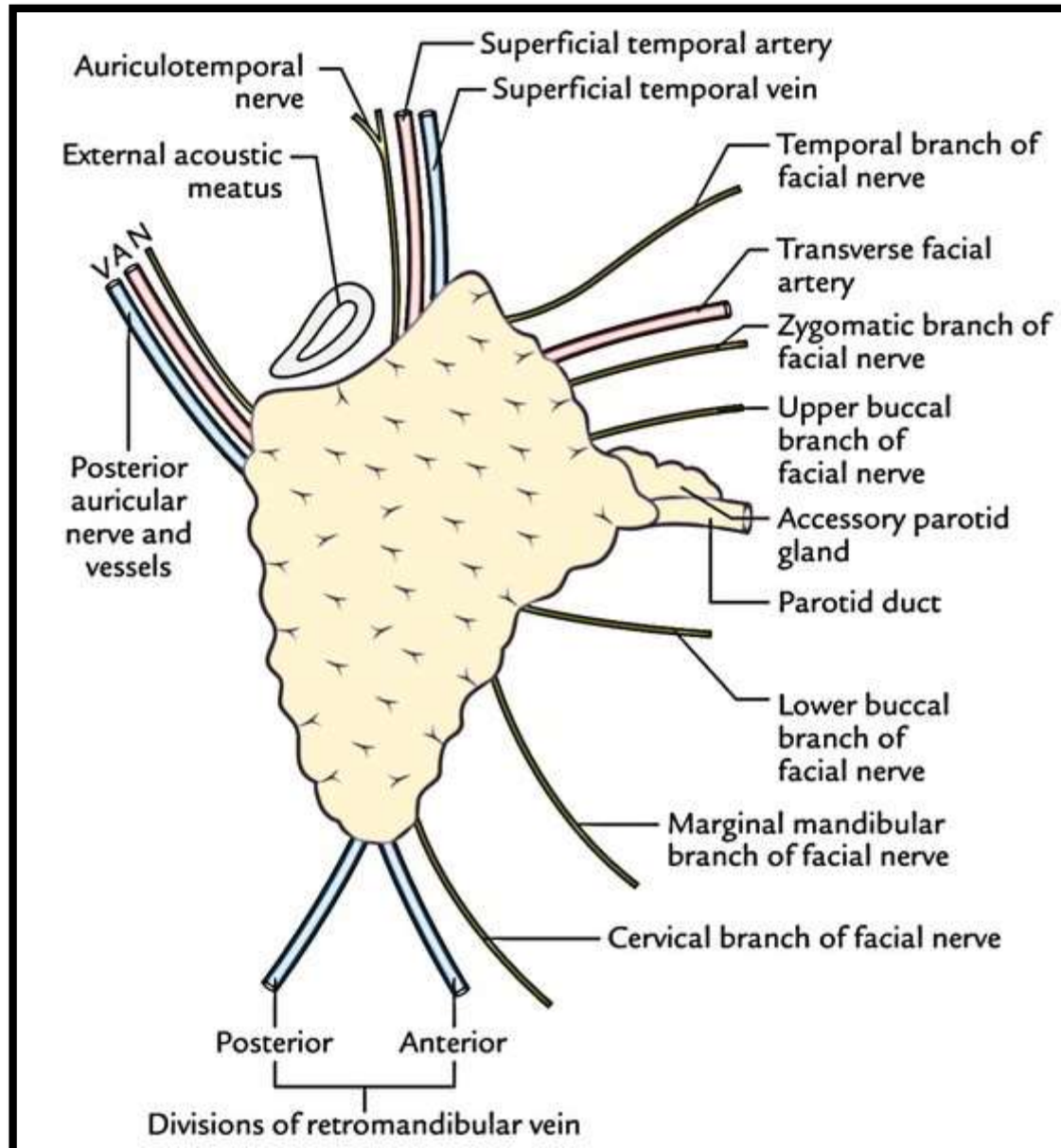
- Molded onto mastoid and styloid processes.



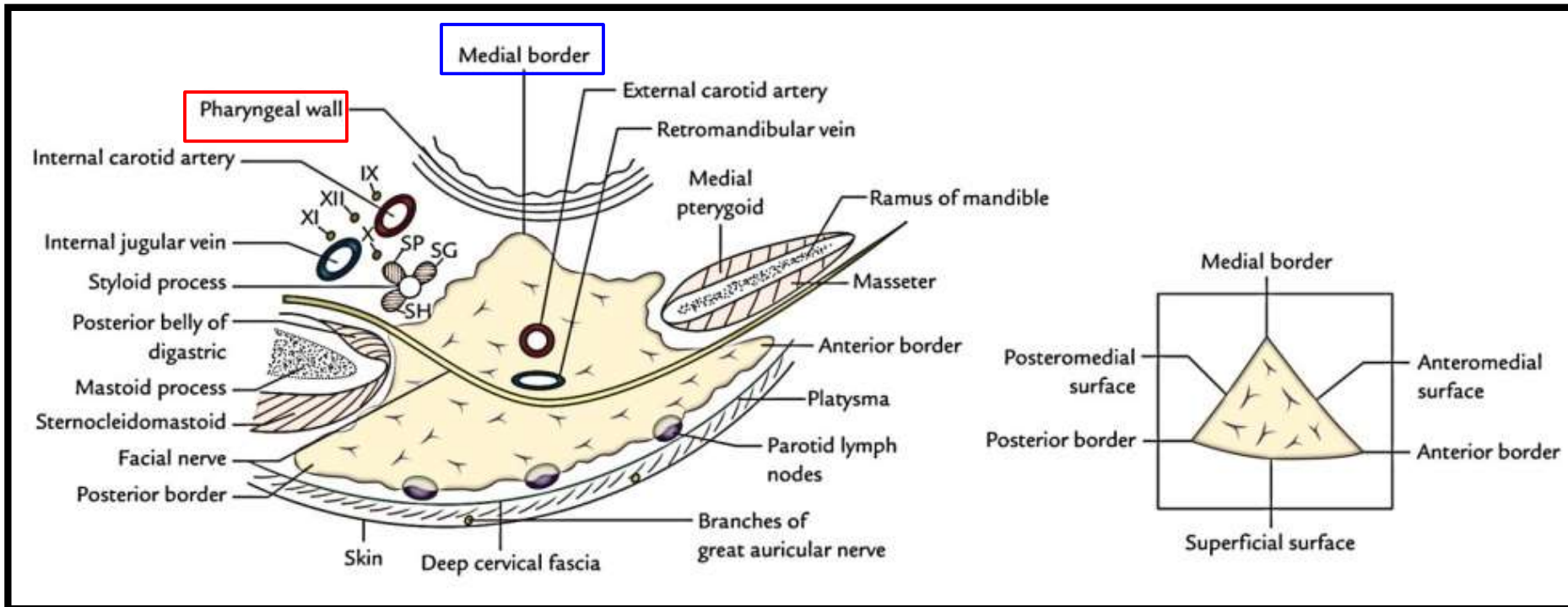
# Structures entering into Posteromedial surface



# Relations of Anterior and Posterior borders



# Relations of Medial border

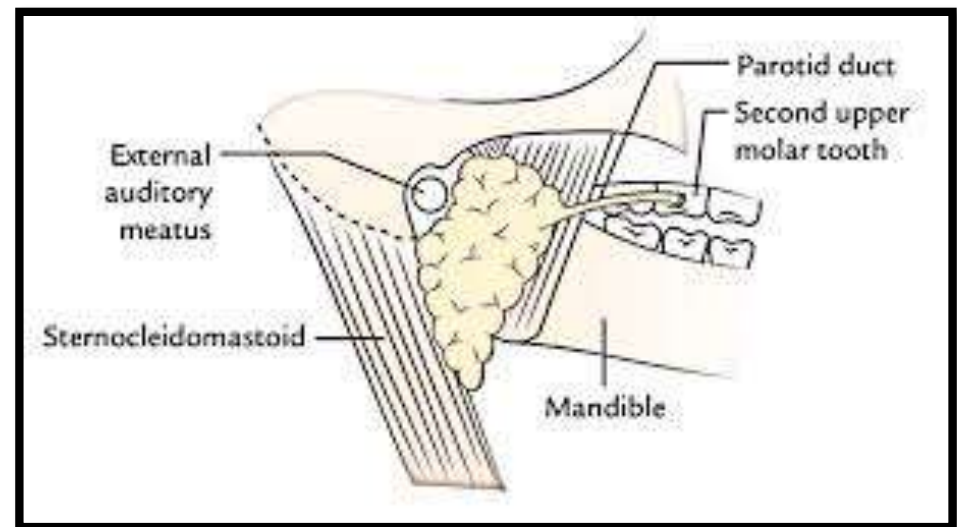
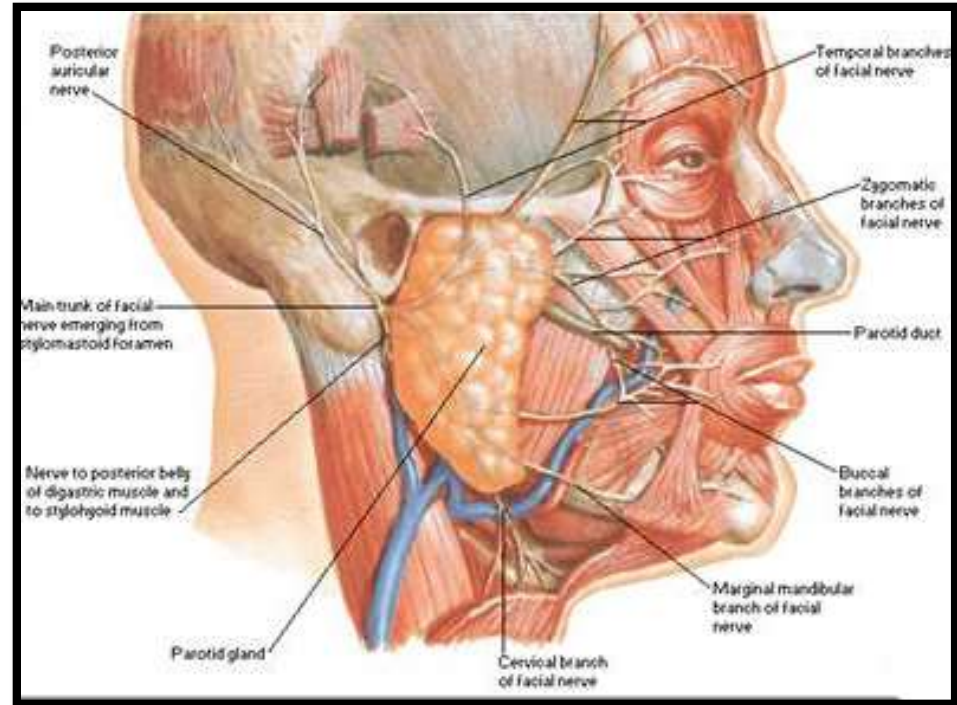


# Parotid Duct/Stenson's Duct

**Length** – 5 cm

**Direction-** Forwards and slightly downwards on masseter.

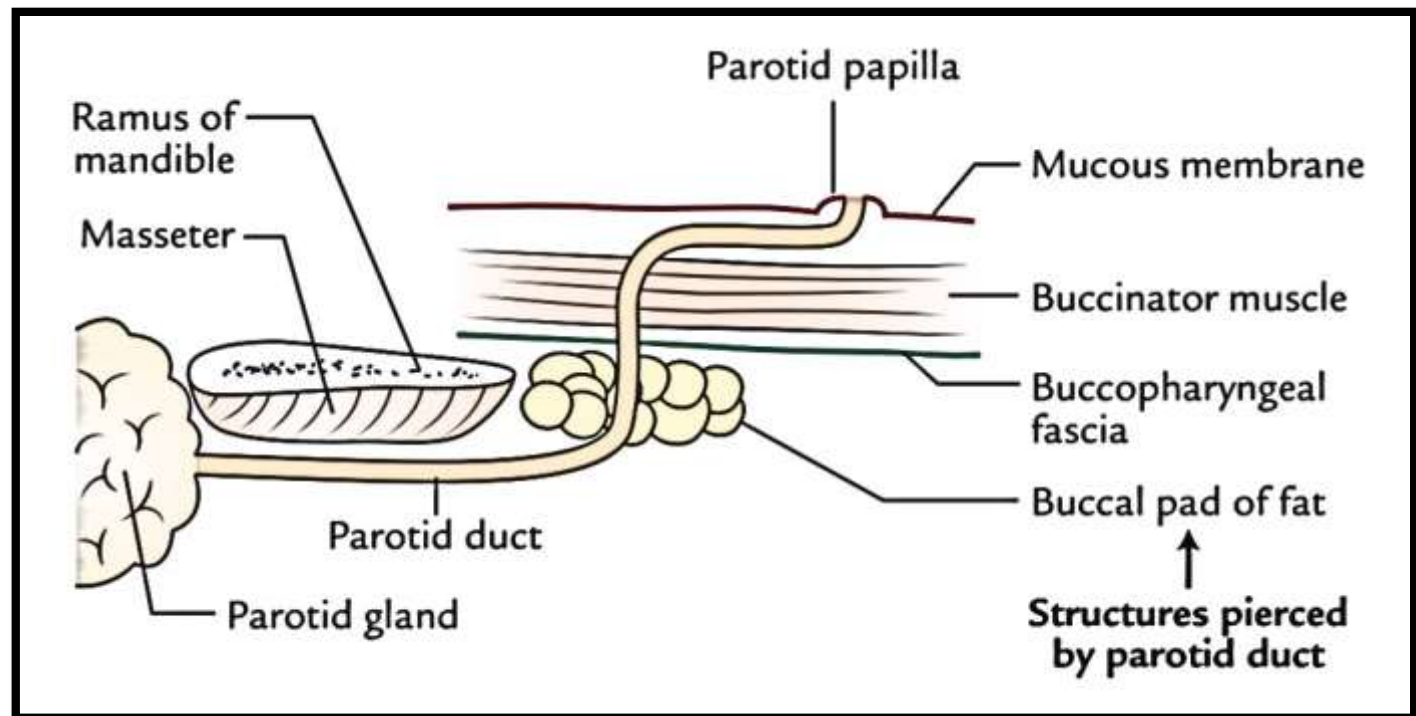
- It runs between buccinator and oral mucosa and opens into the vestibule of mouth opposite the crown of **upper second molar** tooth.



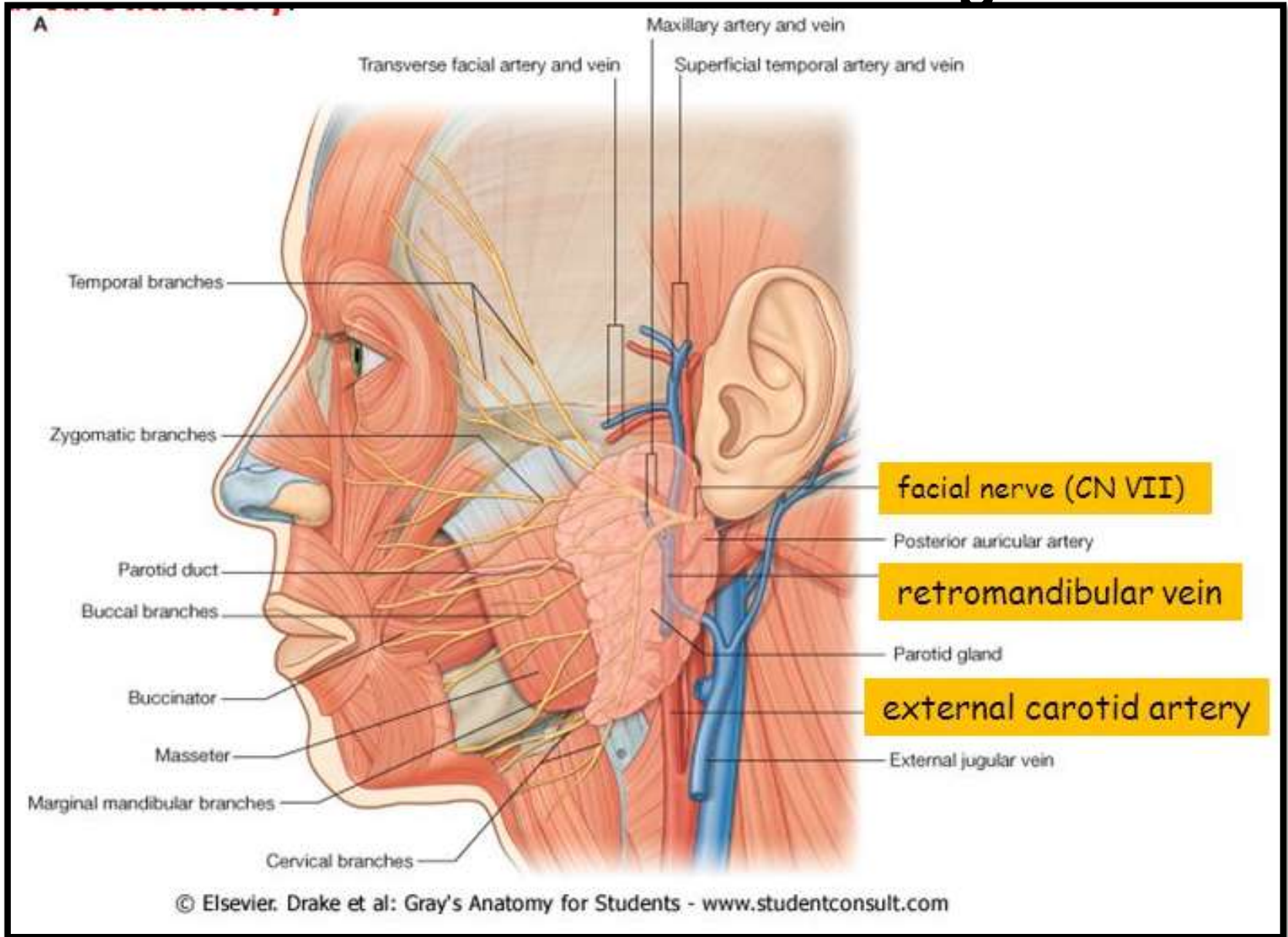


# Parotid Duct/Stenson's Duct contd...

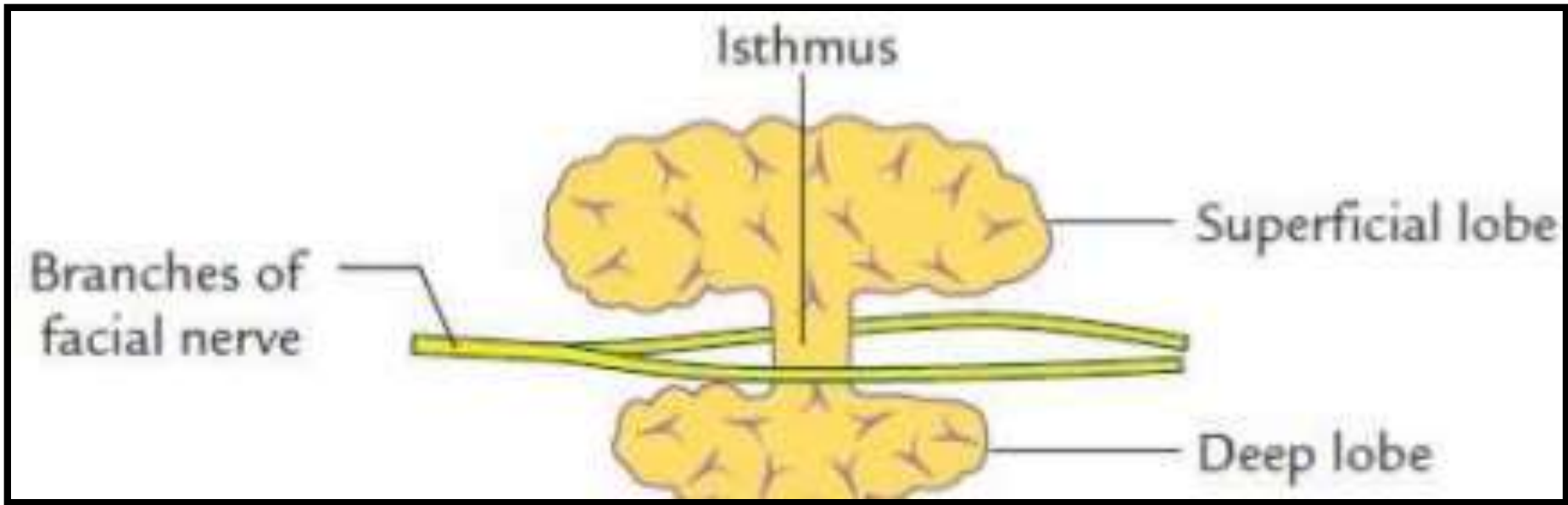
- It pierces:
  1. buccal pad of fat
  2. buccopharyngeal fascia
  3. buccinator muscle
  4. buccal mucosa



# Structures within Parotid gland



# Lobes of Parotid Gland & Patey's Fasciovenous Plane



# Frey's Syndrome

