

Evaluation of Spinal Injury & Emergency Management

Dr. Shah Waliullah

MS DNB MCh Dip SICOT PhD

KGMU, Lucknow

INTRODUCTION

□ Spinal injury” may be defined as-Injury to the Spinal column (Bony Column)/Spinal Cord, or both of them.

can be divided into-

□ Spinal Column Injury.

□ Spinal Cord Injury.

□ Combined (Both Column & Cord) Injury.

OVER VIEW

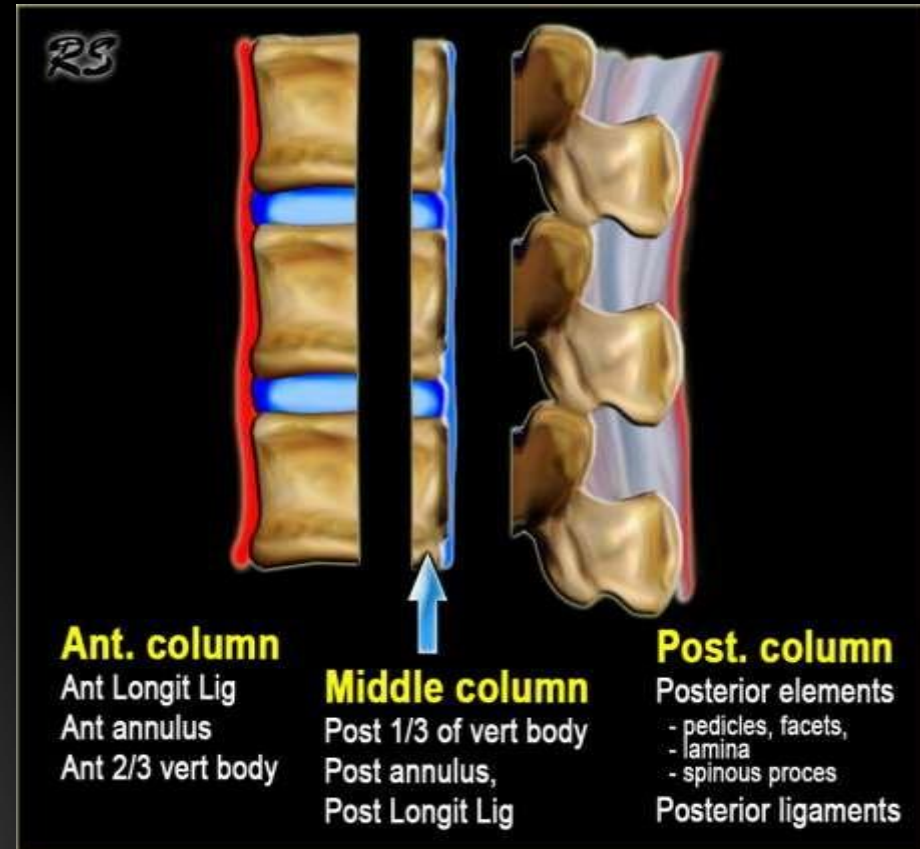
- Traumatic Spinal Cord Injury accounts for 12,000 new cases each year.
Mortality/Morbidity
 - 94% of patients survive the initial hospitalization
 - Life Expectancy is greatly reduced.
 - Renal Failure ,leading cause of death in the past.
 - Currently, Pneumonia, Pulmonary Emboli, and septicemia are the major causes.
- Commonly men 16–30 years old (M:F Ratio 4:1)
- Mechanism of Injury
 - Vehicle crashes: 40.4%
 - Falls: 27.9%
 - Penetrating trauma: 15%
 - Sports injury: 8%

CONT....

- Most common vertebrae involved are C5, C6, C7, T12, and L1 because of greatest ROM.
- 25% of all spinal injuries occur from improper handling of the spine and patient after injury.

DENIS-THREE COLUMN CONCEPT OF SPINAL STABILITY.

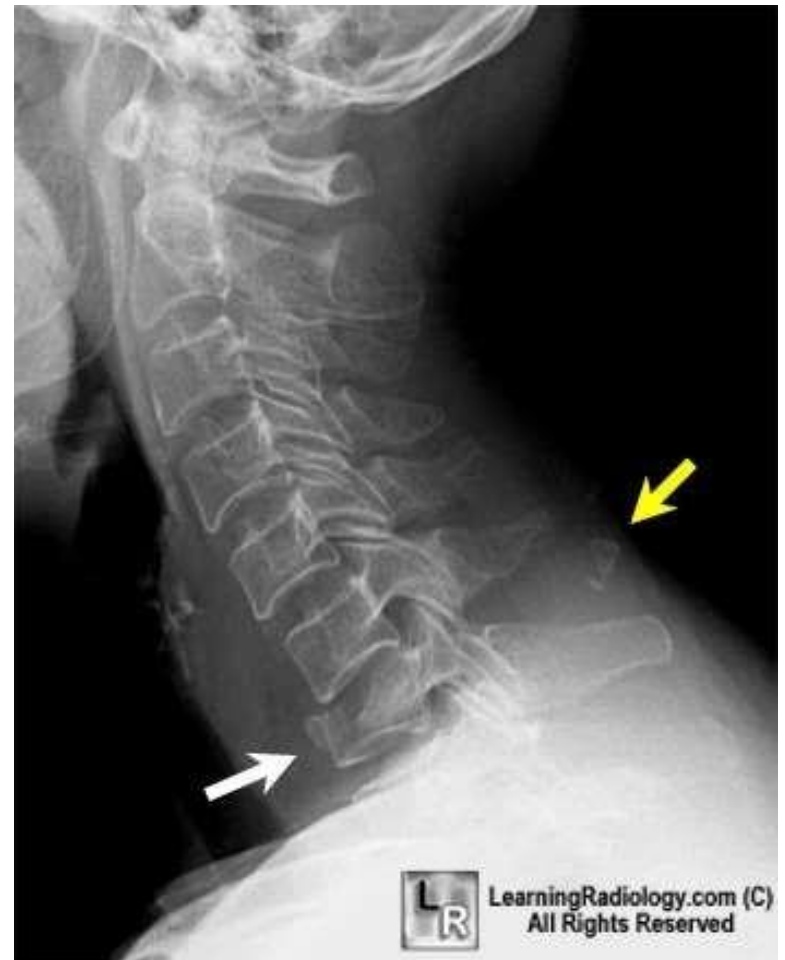- The spinal cord can be divided into three columns:
 - Anterior
 - Middle
 - Posterior.
- Spinal stability is dependent on at least two intact columns.
- When two of the three columns are disrupted, it will allow abnormal segmental motion, i.e. instability.



SPINAL REGION OVERVIEW

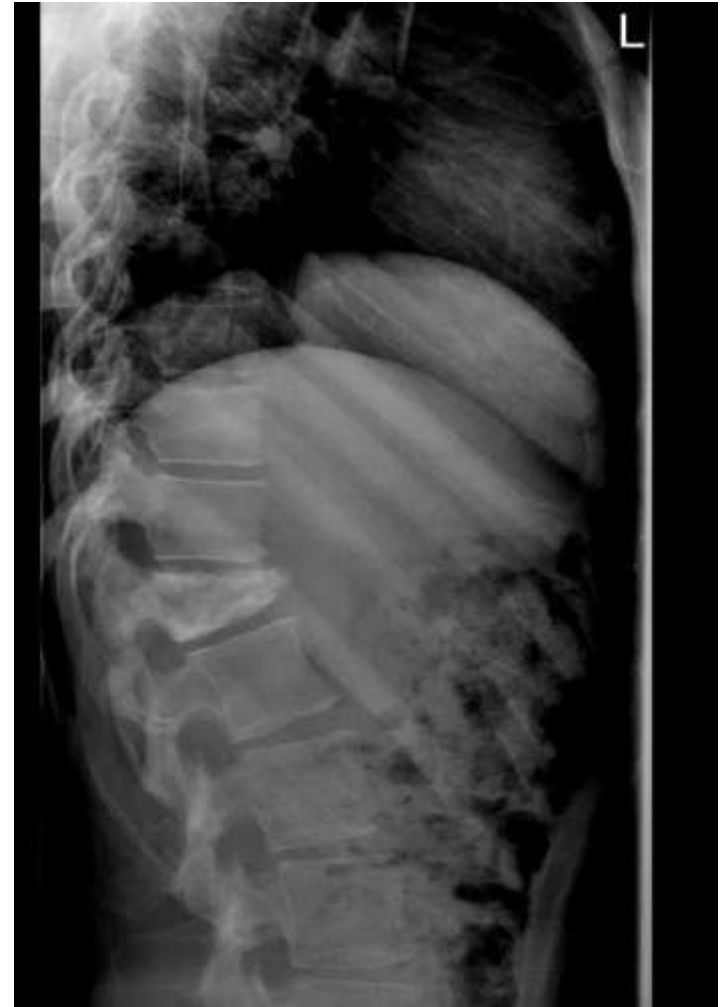CERVICAL SPINE INJURIES

- 55% in cervical region
 - C-spine very flexible
 - Mobile & exposed
 - Most frequently injured area of spine
- Most injuries at C-5/C-6 level



THORACIC SPINE INJURIES

- 15% in thoracic region
- Less mobile & protected
 - Narrow spinal canal
 - Cord injury with minimal displacement
- Common mechanisms
- Any cord damage usually complete at this level

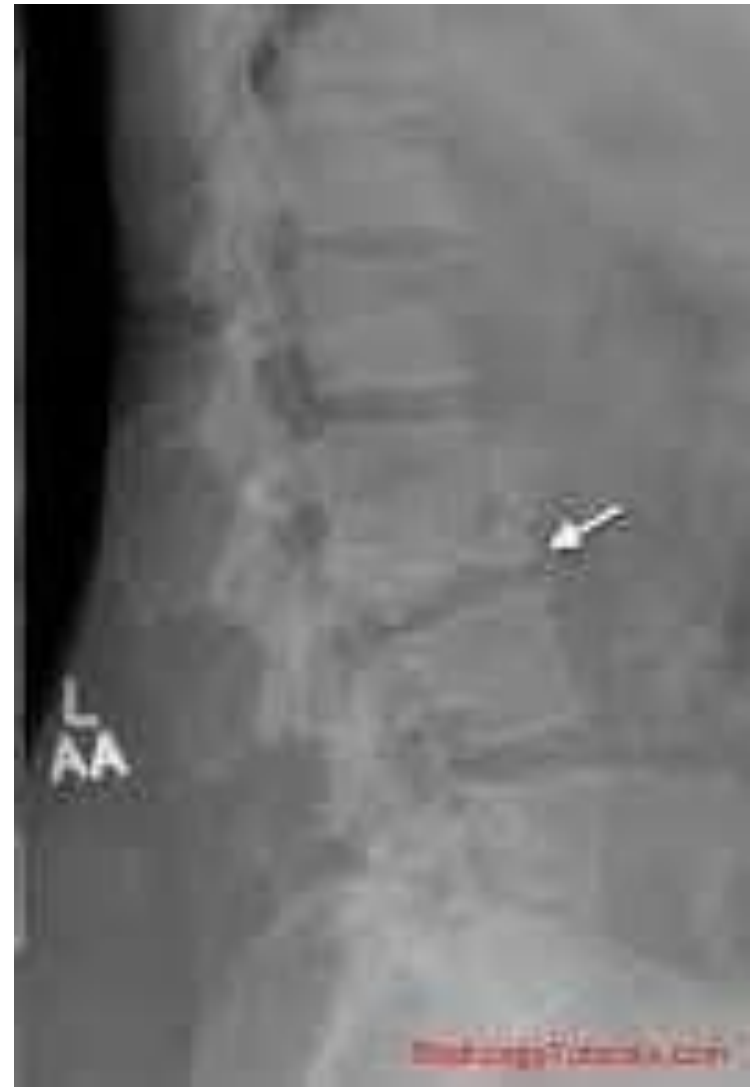

THORACOLUMBAR INJURIES

- 15% in thoracolumbar region
- Fulcrum
- Transition zone prone to injury

LUMBOSACRAL SPINE INJURIES

- 15% in lumbosacral region
- LS spine flexible nerve roots in roomy spinal canal
 - May have bony injury w/o cord or nerve root damage
- Secondary injury still possible
- Neurological injury rare with isolated sacral injuries



REGIONAL VARIATIONS

- **Upper Cervical Region** Designed to facilitate motion Canal is spacious.

Injury is uncommon

- **Cervicothoracic Junction** Transitional zone from mobile to fixed Prone to injury.

- **Thoracic Spine**

Rigid because of stabilizing influence of the thorax.

Associated vascular and visceral injuries are common.

- **The Thoracolumbar Junction**

Transitional zone and also prone to injury.

SPINAL CORD INJURY: CLASSIFICATION

Spinal cord injury may be categorized as:

- Incomplete Quadriplegia (incomplete cervical injury)-39.5%
- Complete Quadriplegia-16.3%
- Incomplete paraplegia (incomplete thoracic injury)-21.7%
- Complete paraplegia-22.1%

SPINAL INJURY: MORPHOLOGY

Spinal injuries can be described as:

1. Fractures
2. Fracture – dislocations
3. Spinal cord injury without radiographic abnormalities
4. Penetrating injuries

These injuries can be further categorized as **stable** or **unstable**.



STABLE VS. UNSTABLE INJURIES

□ **Stable Injuries**

- Vertebral components won't be displaced by normal movement.
- An undamaged spinal cord is not in danger.
- There is no development of incapacitating deformity or pain.

□ **Unstable Injuries**

- Further displacement of the injury may occur.
- Loss of 50% of vertebral height.
- Angulation of thoracolumbar junction of > 20 degrees.
- Failure of at least 2 of Denis's 3 columns.
- Compression fracture of three sequential vertebrae can lead to post-traumatic kyphosis.

TYPES OF SPINAL CORD INJURY

The Primary Injury

- When the skeletal structures fail to dissipate the energy of the primary mechanical insult.
- Direct trauma & energy transfer to neuronal elements.
- Haematoma & SCIWORA < 8yrs old
- In 4hrs -Infarction of white matter occurs
- In 8hrs -Infarction of grey matter and irreversible paralysis.

The Secondary Injury

- Hypoxia
- Hemorrhage & Hypoperfusion
- Oedema
- Neurogenic shock secondary to the insult.
- Therapeutic strategies are directed at reducing secondary injury.

MECHANISMS OF SPINAL INJURY

Hyperextension:

- Common in the neck
- Anterior ligaments and disc may be damaged.

Hyperflexion:

- If posterior ligament is intact , wedging of vertebral body occurs. If torn , may cause subluxation.

Axial compression:

- Causes burst fractures. Bony fragments may be pushed into spinal canal.

Flexion with rotation:

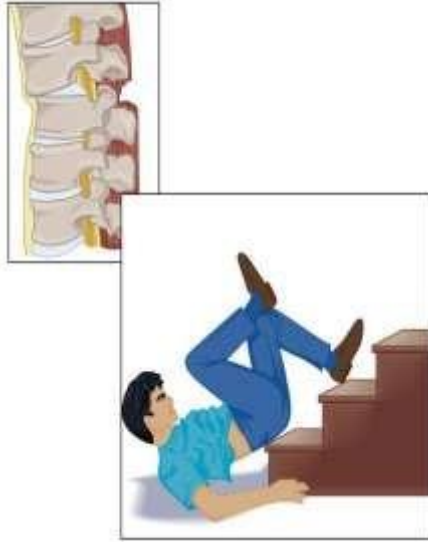- Causes dislocation with or without fracture.

Flexion with posterior distraction:

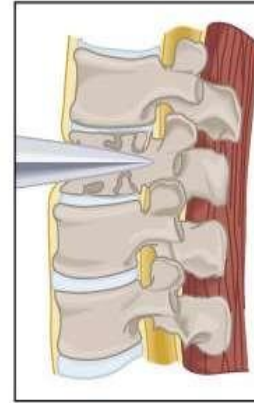
- May disrupt middle and posterior column

SPINAL CORD INJURIES

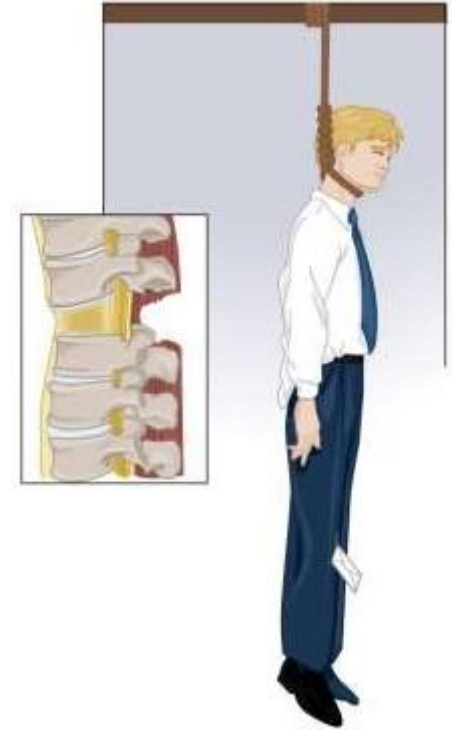
FLEXION INJURY



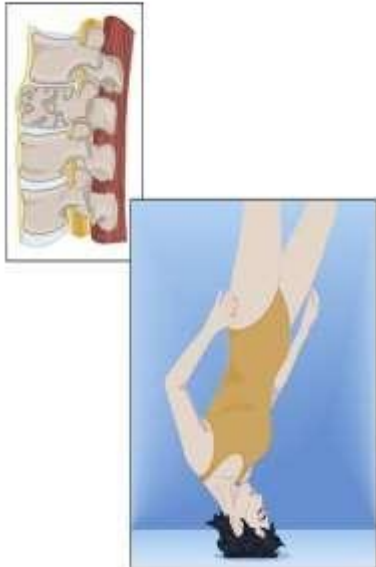PENETRATION INJURY



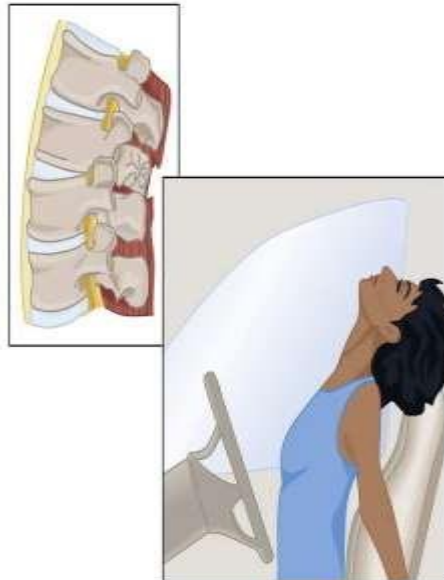
DISTRACTION INJURY



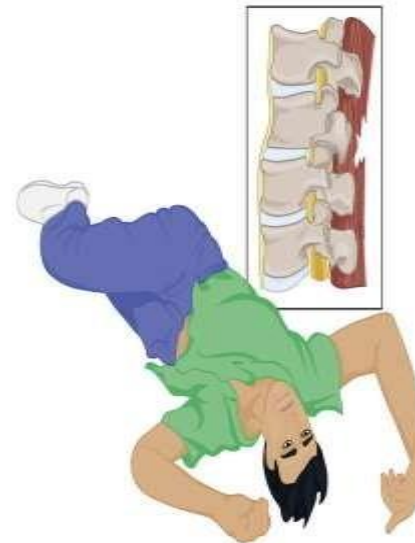COMPRESSION INJURY




HYPEREXTENSION INJURY




FLEXION-ROTATION INJURY




RISK FACTORS

- Alcohol intoxication
 - Drug abuse
 - High-risk activities
 - Diving
 - Contact sports
 - Osteoporosis
- 

EVALUATION OF PATIENT

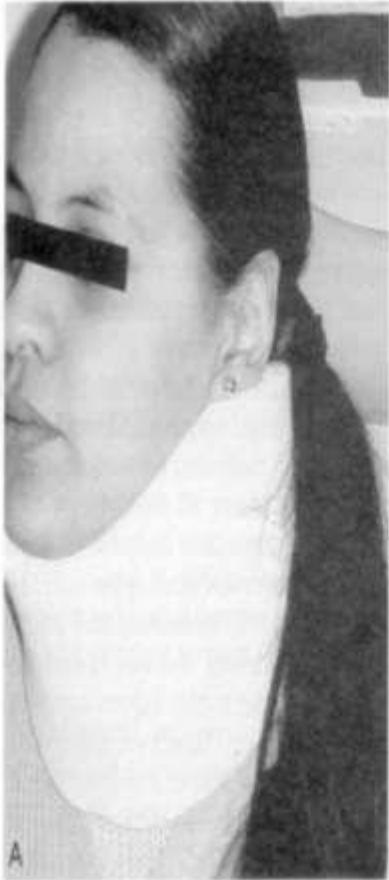- Approach every patient in the same manner using **Advanced Trauma Life Support Principles (ATLS)**.
 - Assume every trauma patient has a spinal injury until proven otherwise.
 - All Assessment, Resuscitation and life saving procedures must be performed with full immobilization.
- 

SUSPECTED SPINAL INJURY

- Polytrauma patient
 - Compression injury (diving, fall on buttock)
 - Neurological Deficit
 - Multiple Injuries
 - Head Injuries & unconsciousness
 - Facial Injury
 - High energy Injury
 - Blunt Trauma Abdomen
 - Abdominal Bruising from a seatbelt.
 - Spinal pain/tenderness
- 

SPINAL TRAUMA: PRIMARY SURVEY

- Activate trauma team.
- Move patient off spinal board as soon as clinically safe
- **Airway maintenance with C-spine immobilization**
Definitive airway early if respiratory compromise (Injury higher than C6 need intubation and ventilation) Maintain hard collar, sandbag/bolsters and tape
- **Breathing and Ventilation**
Oxygen + ventilator support
Monitor RR, respiratory effort, cough



SPINAL TRAUMA: PRIMARY SURVEY

Circulation with haemorrhage control

If hypotension – hypovolaemic vs neurogenic shock

Assume hypovolaemia 1st : search for source blood loss + replace fluids

-If SC injury: guide fluid replacement with CVP monitoring (controversial)

-Inotropes may be required

CONT....

□ **Disability**


- GCS /pupils
- Look for paralysis/paresis/priapism/anal sphincter tone/
bulbocavernosus reflex

□ **Exposure/Environment**

- Keep warm (blankets, fluid warmer)

Peripherally vasodilated, unable to regulate temp if injury
above T4

ADJUNCTS TO PRIMARY SURVEY

- Full non invasive monitoring
 - ECG
 - Trauma X-ray series – lateral cervical spine, chest, pelvis
 - Bedside FAST scan (sources of bleeding)
- 

SPINAL TRAUMA: SECONDARY SURVEY

- **Assess full spine**

- A. Log roll and palpate spine/ paraspinal region
look for deformity/ crepitus/pain/contusions
/penetrating wounds

- B. Assess for pain, paralysis and parasthesia

Location Neurological level

SPINAL TRAUMA: SECONDARY SURVEY

- Test sensation
 - Test motor function
 - Test deep tendon reflexes
 - DOCUMENT carefully and REPEAT
-
- Head to toe examination – assess for associated injuries

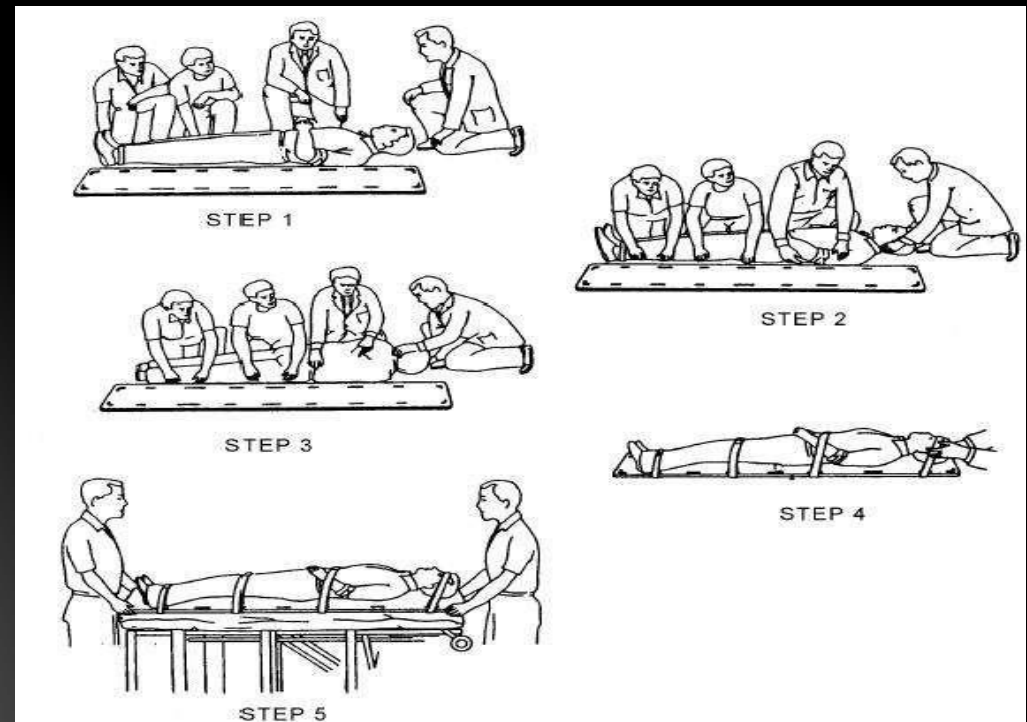
ADJUNCTS TO SECONDARY SURVEY

- Advanced spinal imaging:
 - CT scan (defines bony injury)
 - MRI scan (defines neurological injury)

- Consider CVP monitoring.

SPINAL EXAMINATION

- Spine Log Roll must be performed to achieve proper examination.
- Inspect and palpate entire spine.
- Swelling, tenderness, palpable steps or gaps suggest a spinal injury.
- Note the presence of any wounds that might suggest penetrating trauma.



NEUROLOGICAL EVALUATION


- **American Spinal Injury Association** neurological evaluation system is used.
 - Motor Function assesses key muscle groups. Grade (0-5)
 - Sensory Function assesses dermatomal map. Pinprick and light touch Score: 0-2

Important dermatome landmarks are

- Nippleline–T4
- Xiphoidprocess-T7
- Umbilicus–T10
- Inguinalregion–T12,L1
- Perineum and perianal region (S2,S3&S4)

- Deep Tendon Reflexes
- Rectal examination:
 - Anal tone.
 - Voluntary anal contraction.
 - Perianal sensation.


CONT...

- What should be known after complete neurological examination?
 - Presence or absence of neurological injury.
 - Probable level of injury.
 - Injury is complete or incomplete.
 - Level of impairment.
- 

DIAGNOSTIC IMAGING

- 85% of significant spinal injuries will be seen on standard lateral cervical spine.
- CT Scan should be obtained.
 - Most Sensitive in spinal trauma.
 - Complex patterns and fractures can be understood.
- MRI
 - Best at visualizing soft-tissue elements of the spine.
 - Possible to view spinal cord hemorrhage, epidural and prevertebral hematomas.
 - Not good at assessing bony structures.
- In spinal traumas radiographs and CT scans usually give sufficient information and MRI is not required.

SPINAL CORD INJURY WITHOUT RADIOLOGICAL ABNORMALITY (SCIWORA)

- Spinal cord injury without radiographic or CT evidence of fracture or dislocation
 - With advent of MRI, term has become "Spinal cord injury without neuroimaging abnormality" more correct name.
 - Mostly in pediatric population (Birth to 16 years)
 - Common in cervical and thoracic region
- 

CONT.....

- Following findings on MRI have been recognized as causing primary or secondary spinal cord injury:
 - Intervertebral disk rupture
 - Spinal epidural hematoma
 - Cord contusion
 - Hematomyelia
- Prognosis of SCIWORA is actually better than patients with spinal cord injury and radiologic evidence of traumatic injury.

PROGNOSIS

COMPLETE Neurology

- Total flaccid paralysis
- Total anaesthesia
- Total analgesia
- No tendon reflexes


MUST WAIT UNTIL SPINAL SHOCK RESOLVED to
diagnose

INCOMPLETE Neurology

- Partial paralysis
- Altered sensation (light touch or pin prick)
- Sacral sparing

BETTER prognosis, may recover

THANKS



Regarding whiplash injury, a true statement includes

1. Contusion of spinal cord and fracture of vertebrae
2. Fracture of vertebral body
3. Spinal cord injury without vertebral fracture
4. vertebral fracture without Spinal cord injury

A patient presented with saddle anaesthesia, bladder and bowel involvement. The diagnosis is

1. Injury at L1
2. Injury at L2
3. Injury at L3
4. Injury at L4

Spinal shock is associated with

1. Increased spinal reflexes
2. Loss of autonomic reflexes
3. Bizzare reflexes
4. All of the above

Burst fracture of cervical spine is due to

1. Whiplash injury
2. Fall of weight on neck
3. Axial compression injury
4. Car accident

Burst fracture of cervical spine is due to

1. Whiplash injury
2. Fall of weight on neck
3. Axial compression injury
4. Car accident