

Identification

DR MOUSAMI SINGH
ADDITIONAL PROFESSOR
FORENSIC MEDICINE AND TOXICOLOGY
KGMU

DISCLAIMER

- ▶ The presentation include images which are either hand drawn or have been taken from Google images or books.
- ▶ They are being used in presentation only for educational purpose.
- ▶ The author of the presentation claims no personal ownership over images taken from books or Google images.

Learning objective

- ▷ Corpus Delicti
- ▷ Establishment of identity of living persons including race , Sex , religion , complexion , stature
- ▷ age determination using morphology, teeth-eruption, decay, bitemarks , bones-ossification centres
- ▷ medico-legal aspects of age

- ▶ Identification of criminals ,unknown persons, dead bodies from the remains-hairs, fibers, teeth
- ▶ Anthropometry
- ▶ Dactylography
- ▶ Footprints
- ▶ Scars
- ▶ Tattoos
- ▶ Poroscopy and superimposition

Dental charting

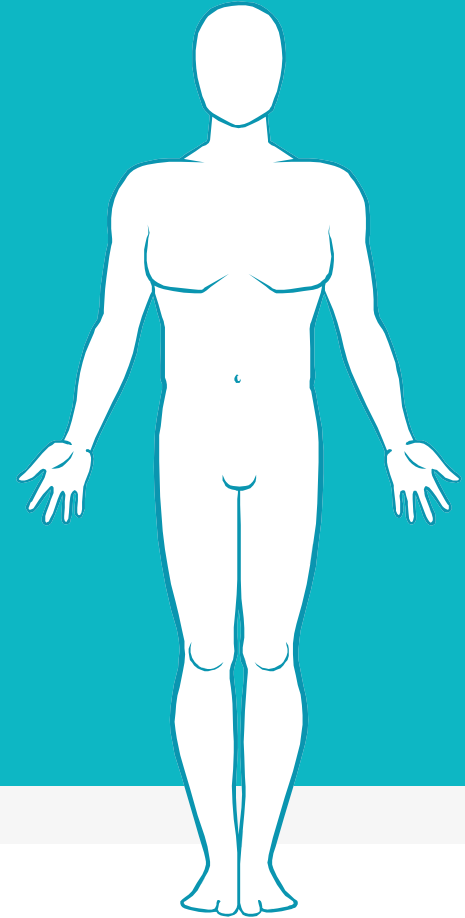
FDI Two Digit Notation

1	2
4	3

5	6
8	7

Permanent Teeth															
upper right								upper left							
18	17	16	15	14	13	12	11	21	22	23	24	25	26	27	28
48	47	46	45	44	43	42	41	31	32	33	34	35	36	37	38
lower right								lower left							
Deciduous teeth (baby teeth)															
upper right								upper left							
			55	54	53	52	51	61	62	63	64	65			
			85	84	83	82	81	71	72	73	74	75			
lower right								lower left							

AGE DETERMINATION FROM SECONDARY SEXUAL CHARACTERS



8

TANNER'S STAGING


- ▷ BEST KNOWN STAGING OF SECONDARY SEXUAL CHARACTERS
- ▷ SMR or Sexual Maturity Ratings


Tanner's stages of breast development (girls)


Tanner's stages of genital development (boys)


Tanner's stages of pubic hair development (both sexes)


Tanner - Tan - 10

I . . .  (10) yr. Stage I is flat (flat appearing chest)
nothing.

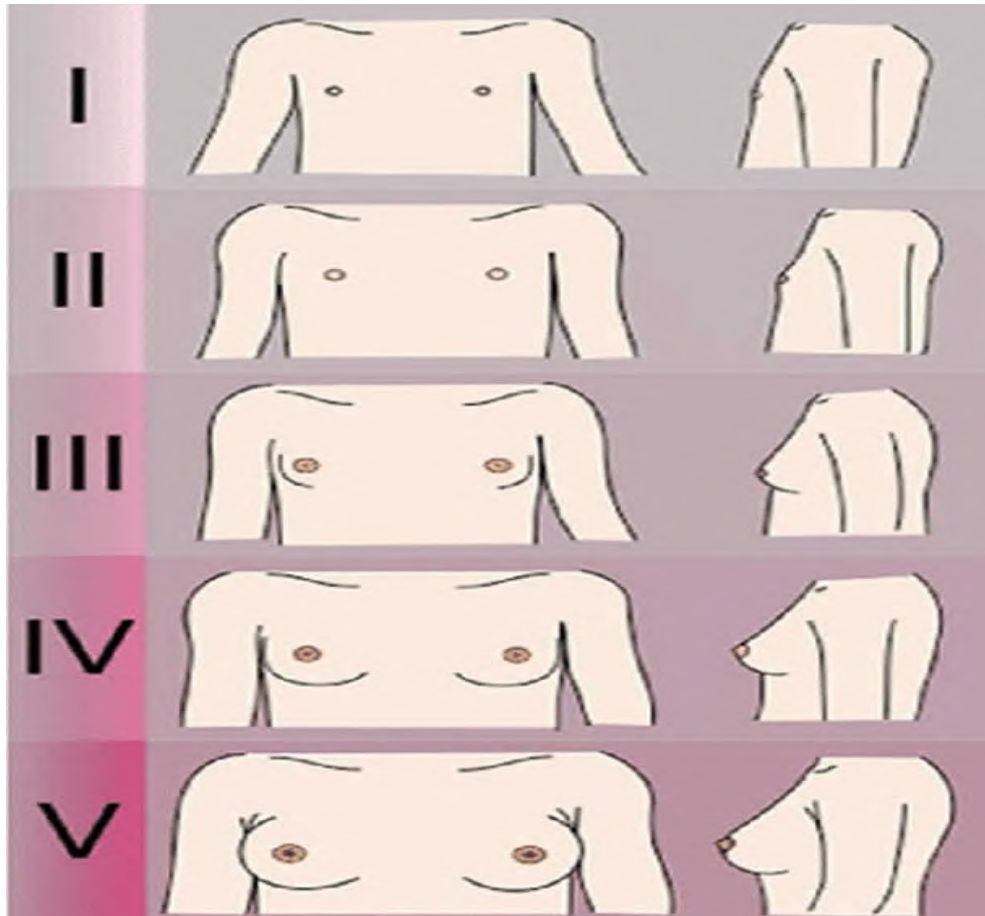
II ○ ○  (11) yr. Breast buds form Thelarche
Breast buds form Thelarche

III ○ ○  (13) yr. III-3
Breast mound forms 3-13 yr old

IV  (14) yr. IV = 14 Puberty nipple raised areola
Two mound, nipple points above areola

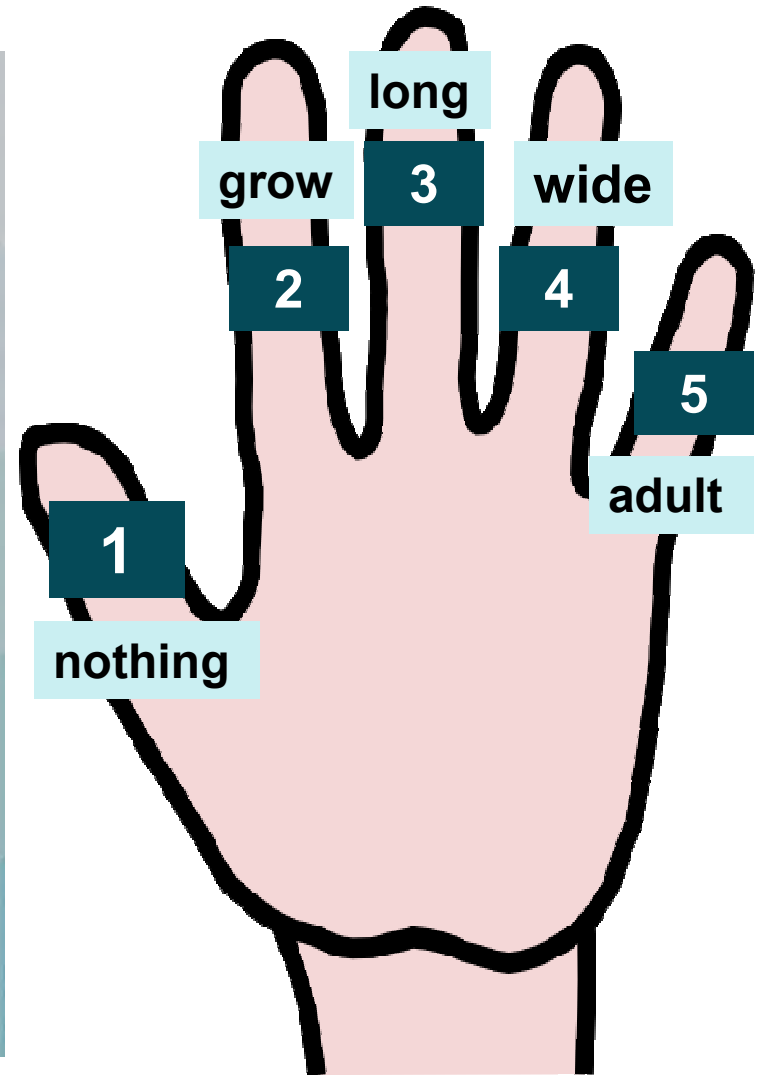
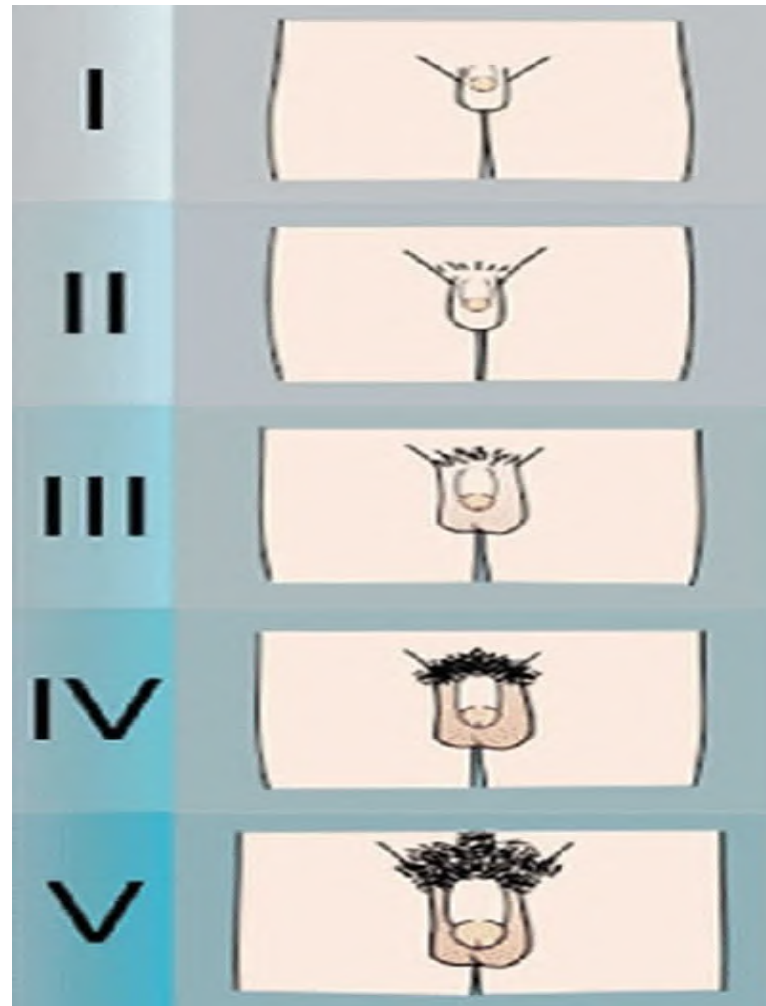
V  V-15 adult.
Areola flattens.
one mound again

Tanner's stages of breast development (girls)

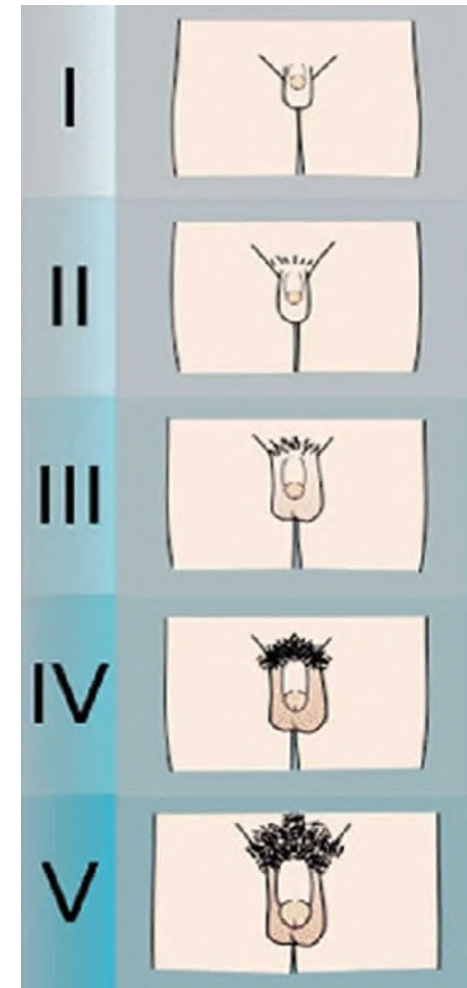
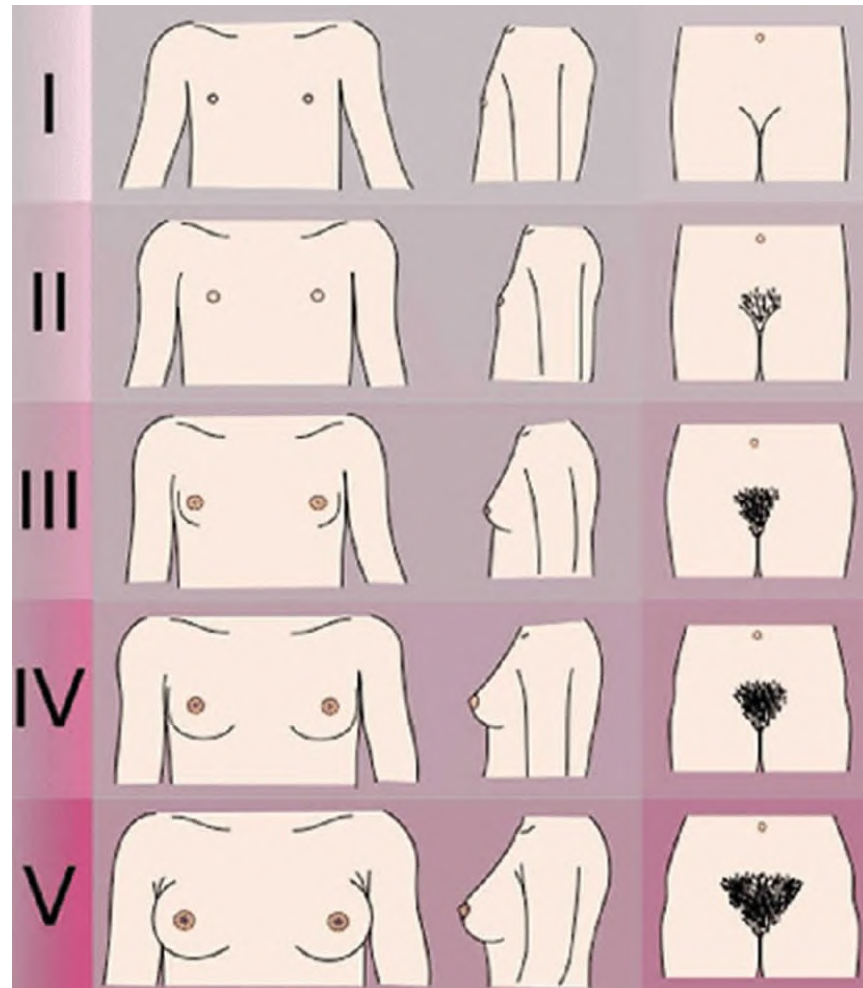


12

TANNER STAGE'S OF GENITAL DEVELOPMENT (BOYS)

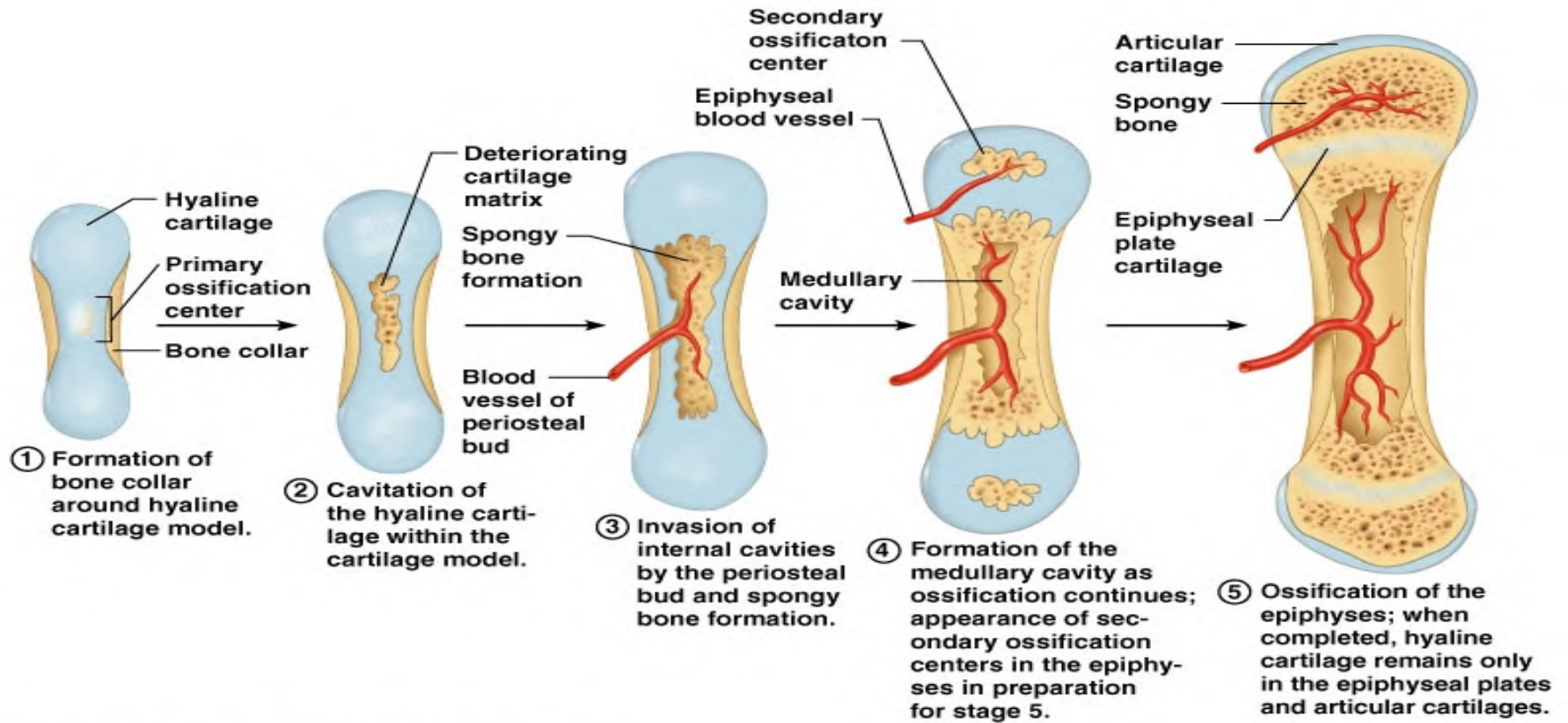


**TANNER
STAGE'S OF
PUBIC HAIR
DEVELOPMENT
(BOTH SEXES)**



Age estimation from ossification activity

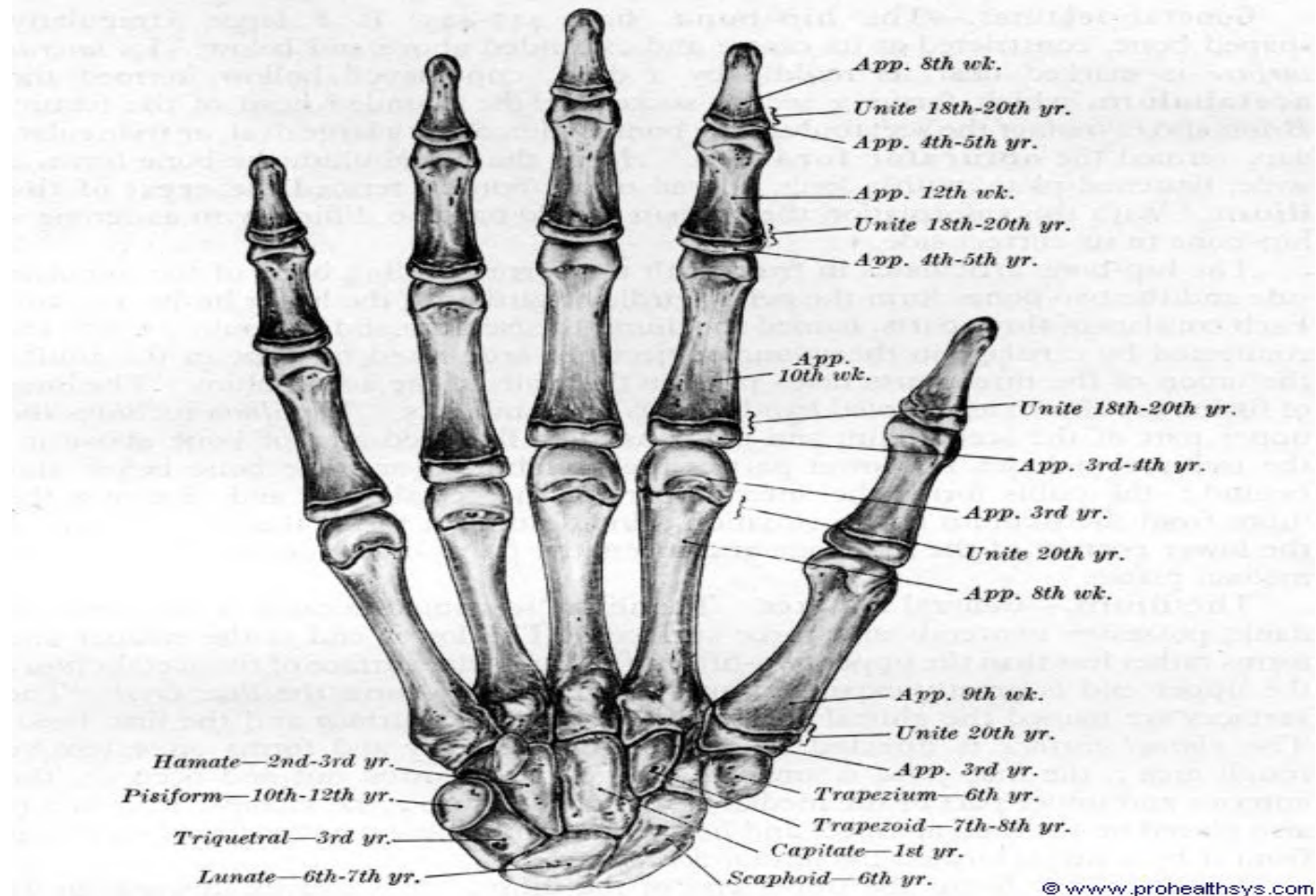






**Hand and wrist
joint**

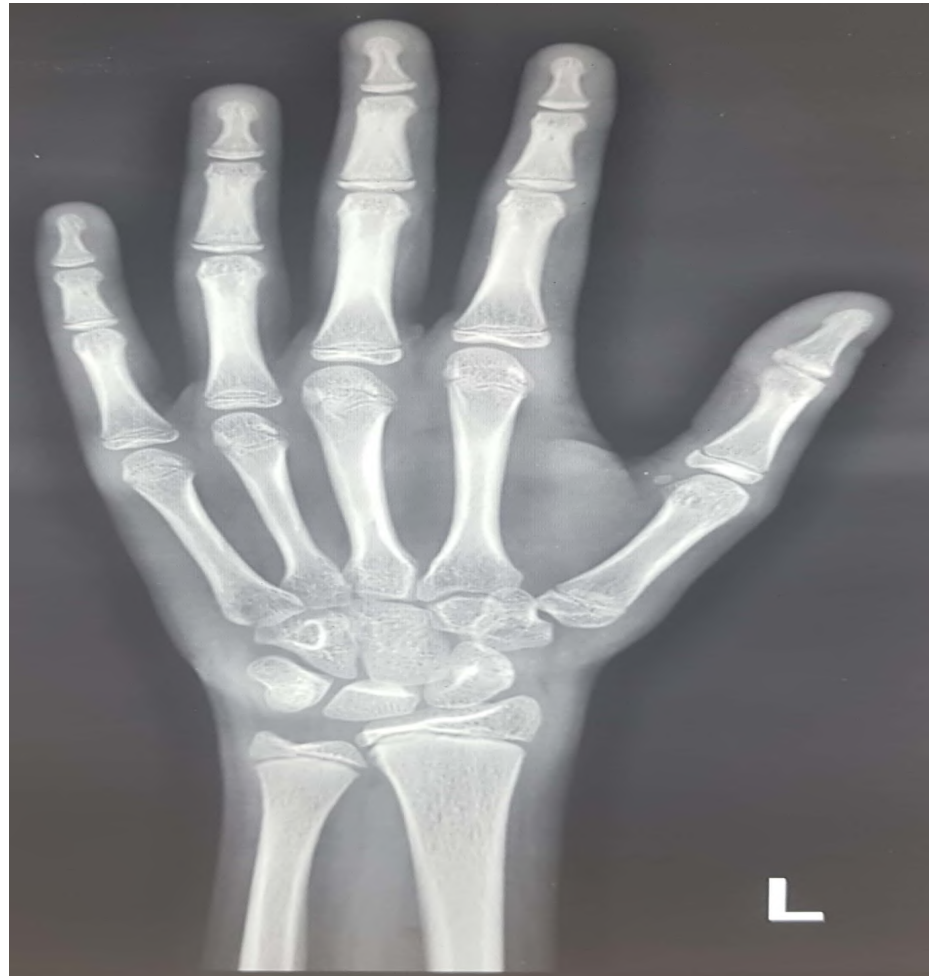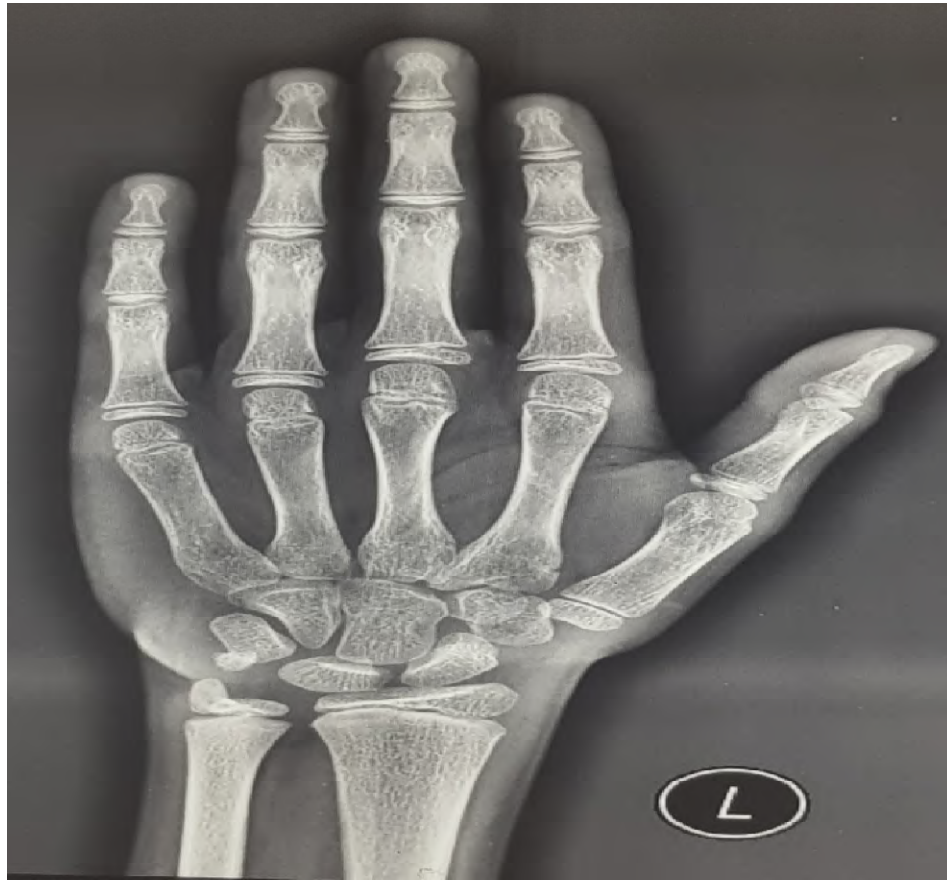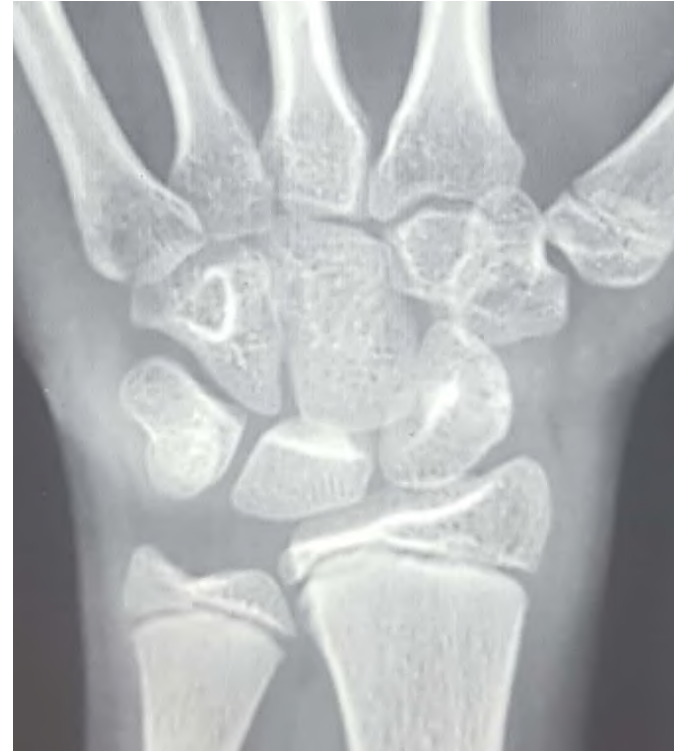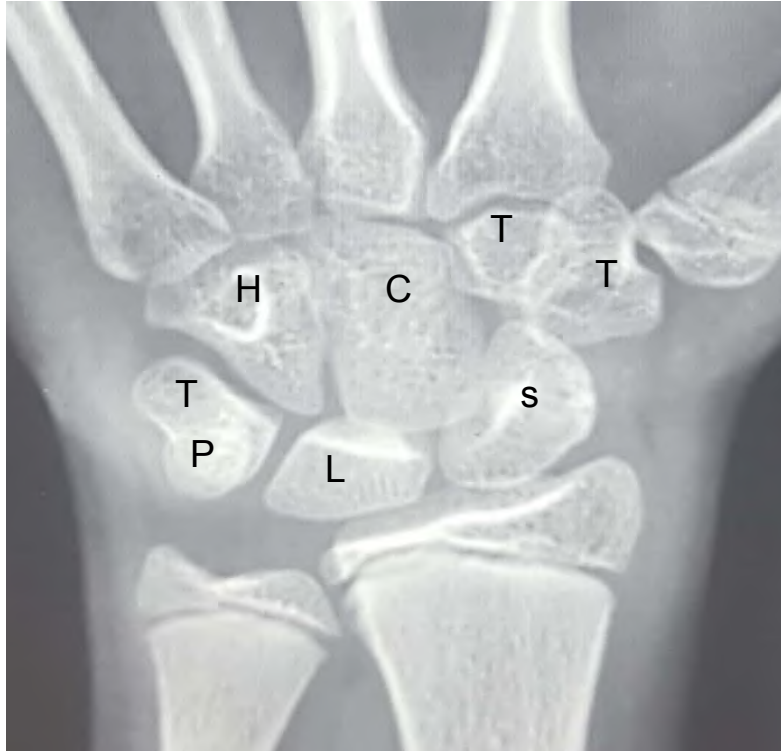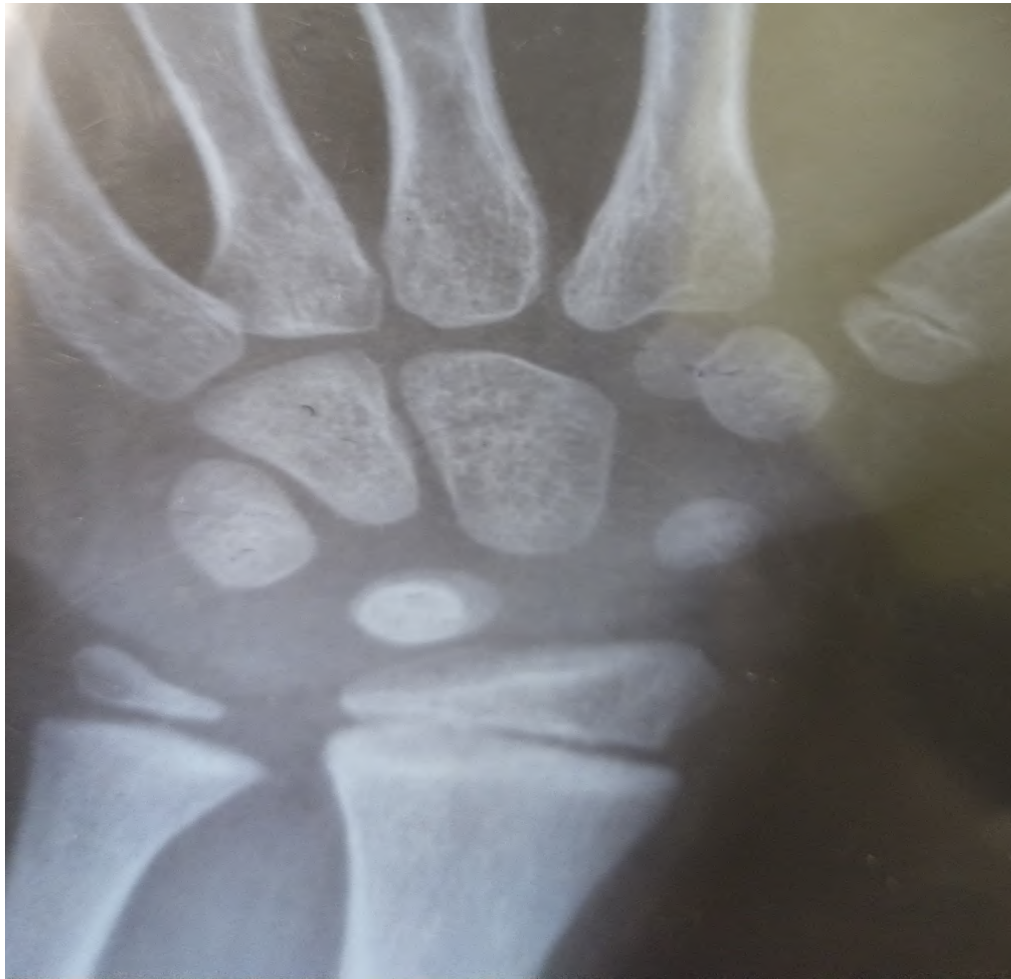



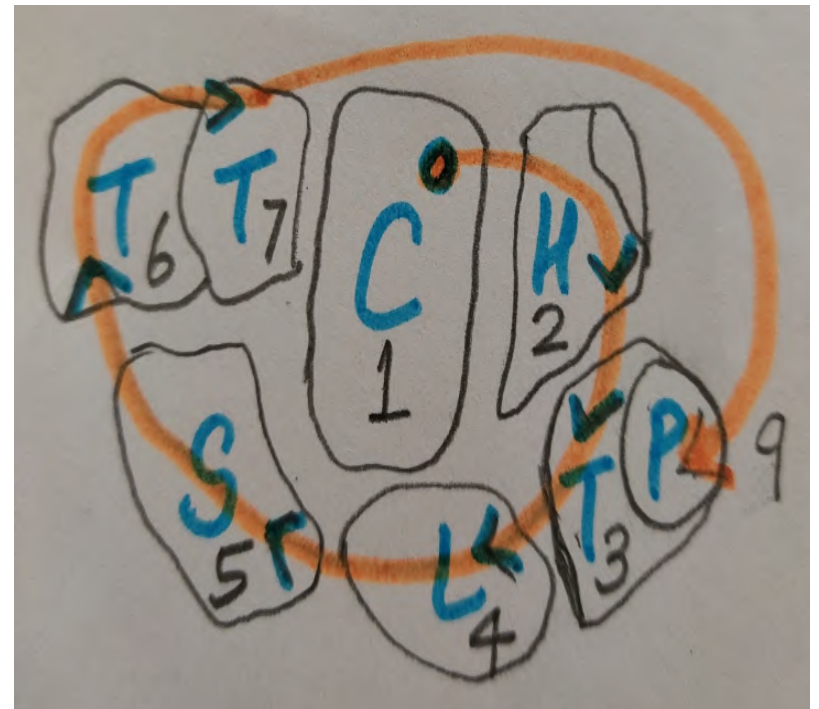
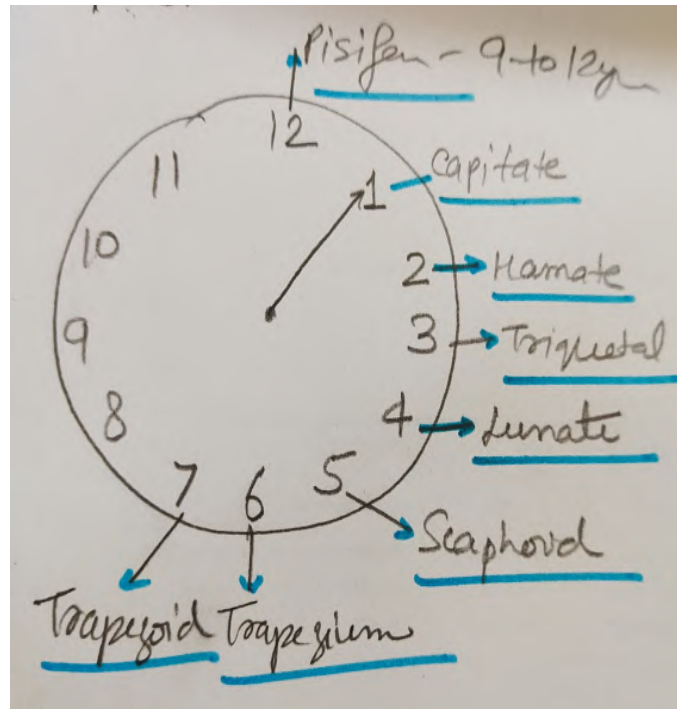
FIG. 441.—The bones of the hand of a child, indicating the general plan of ossification.



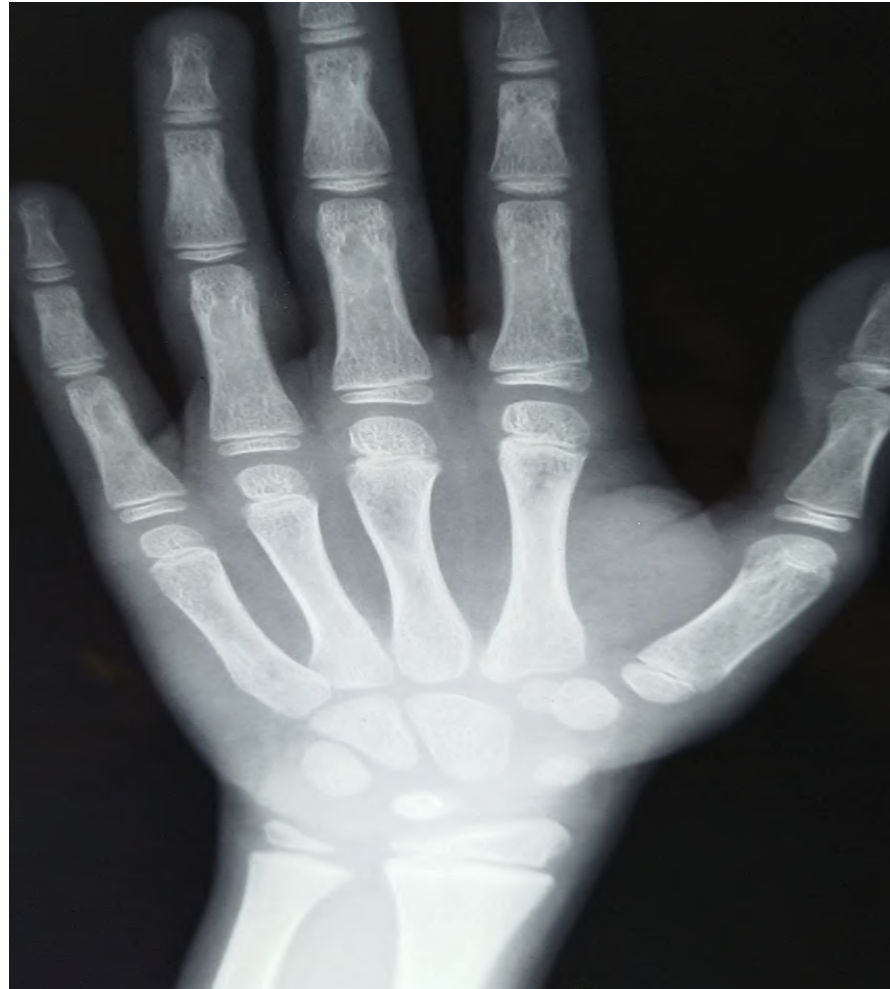


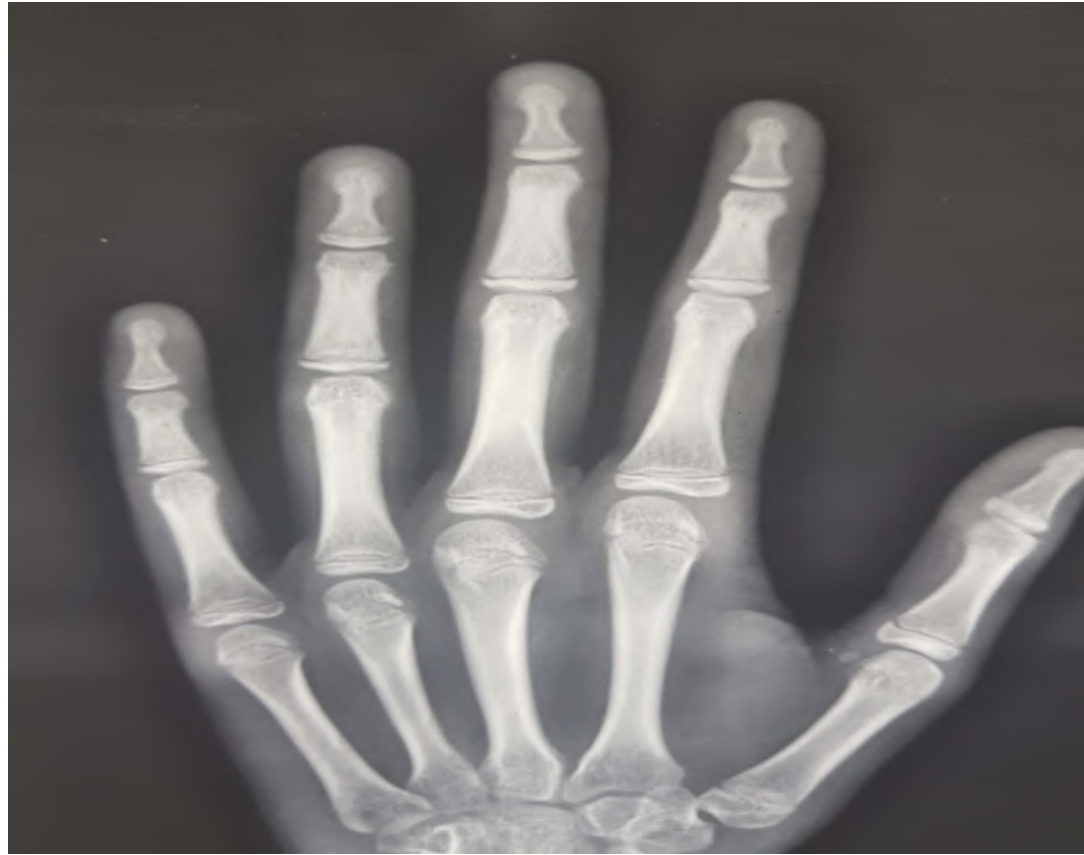


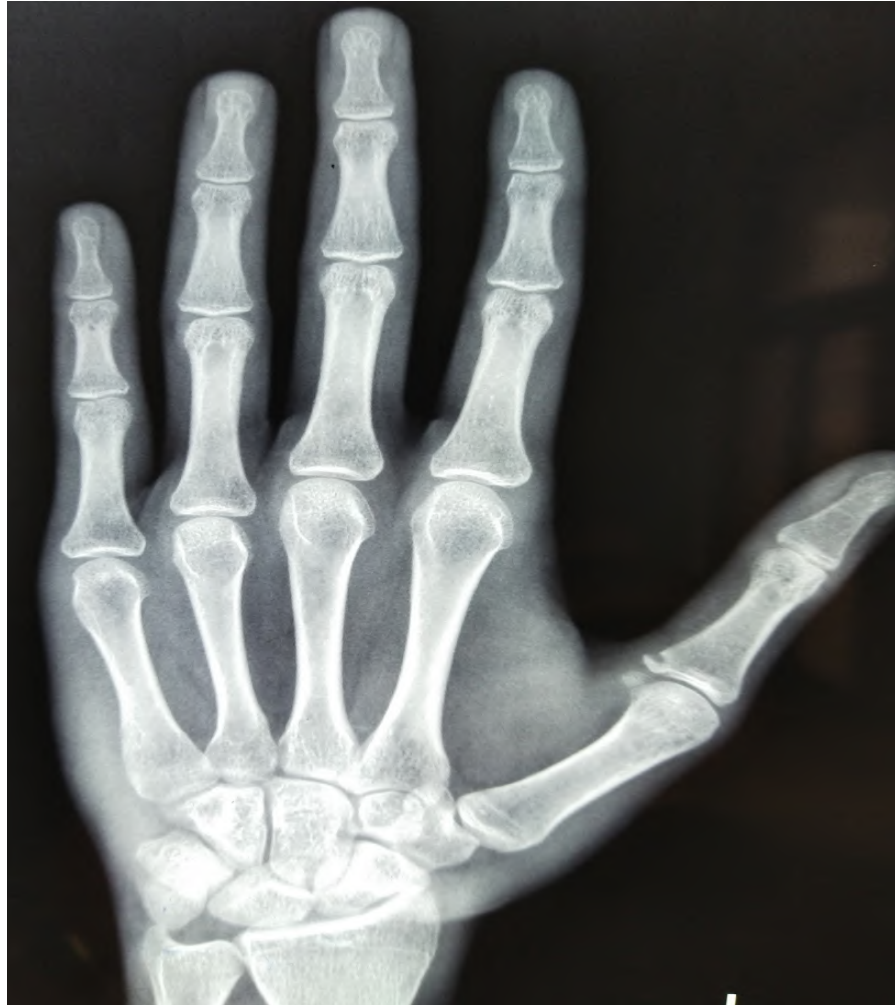



METACARPALS

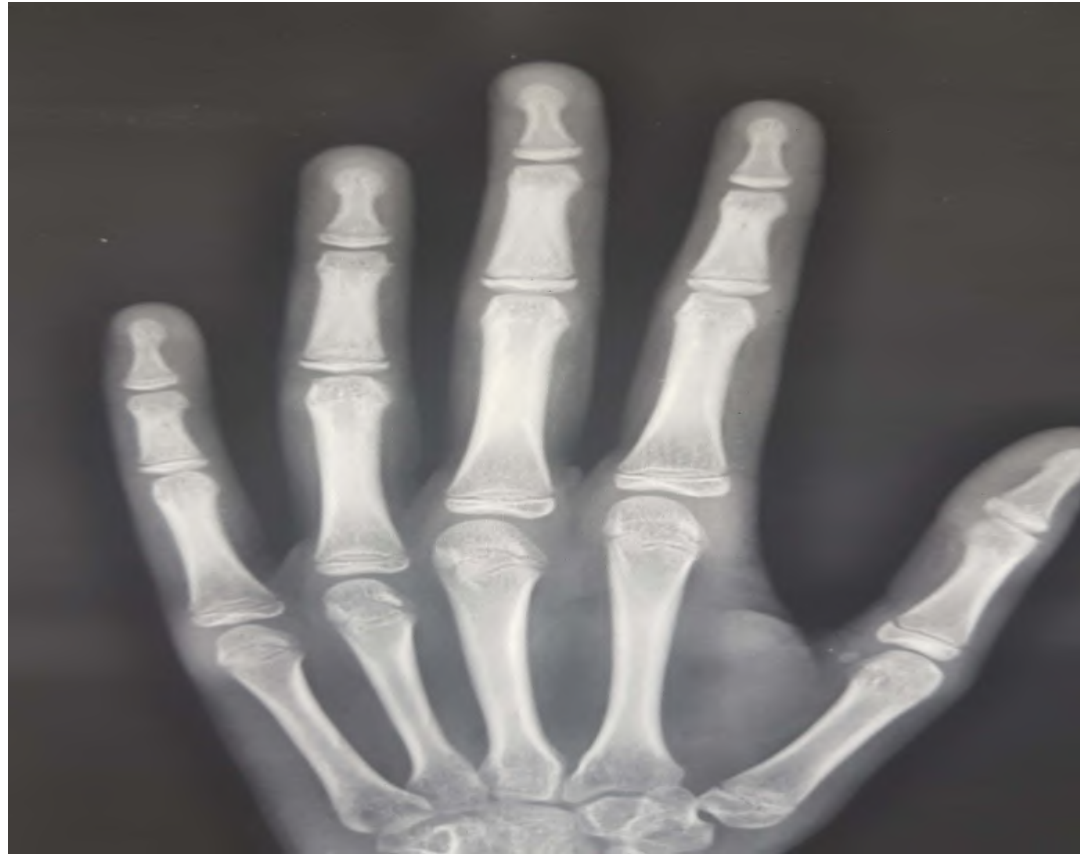






PHALANGES






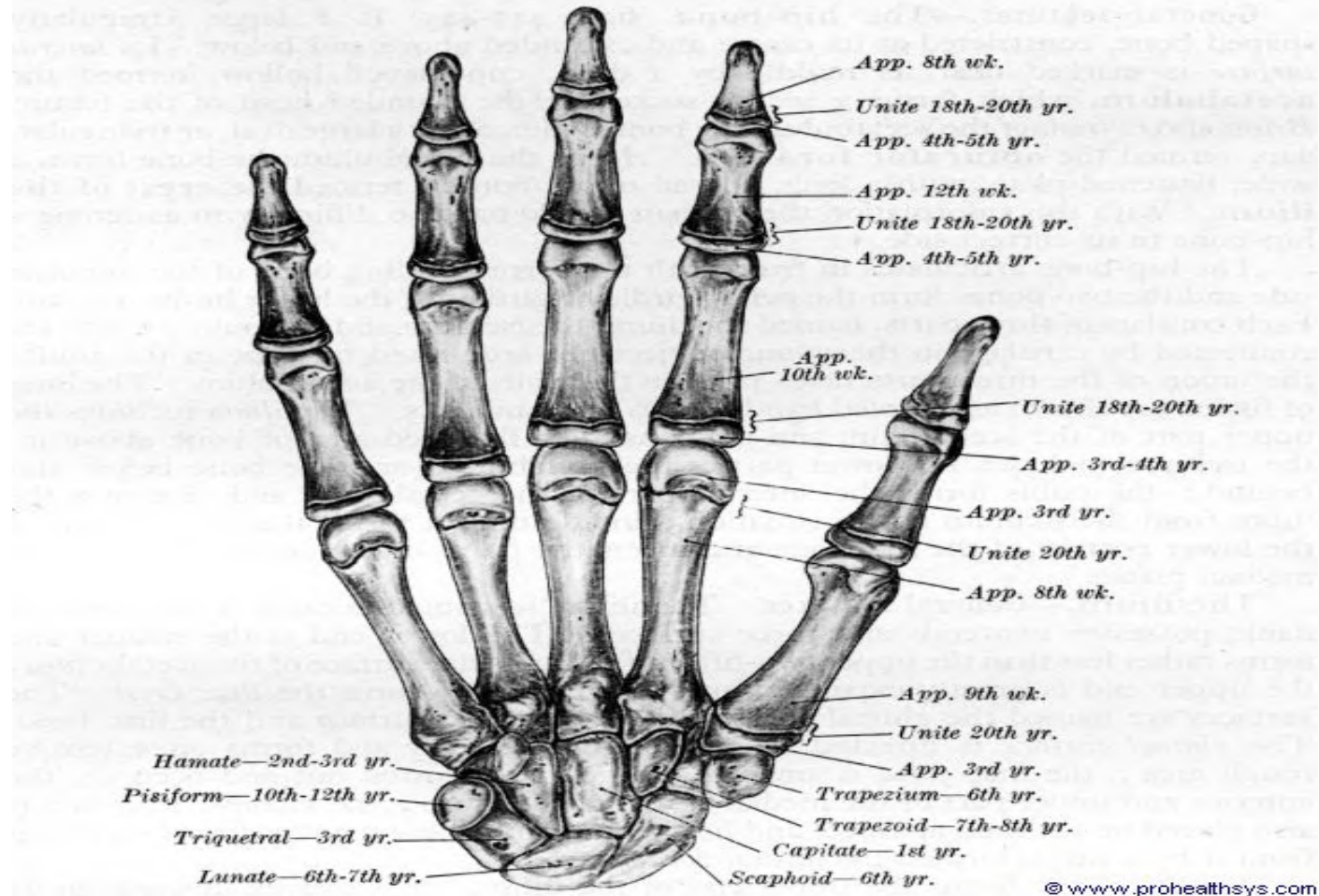
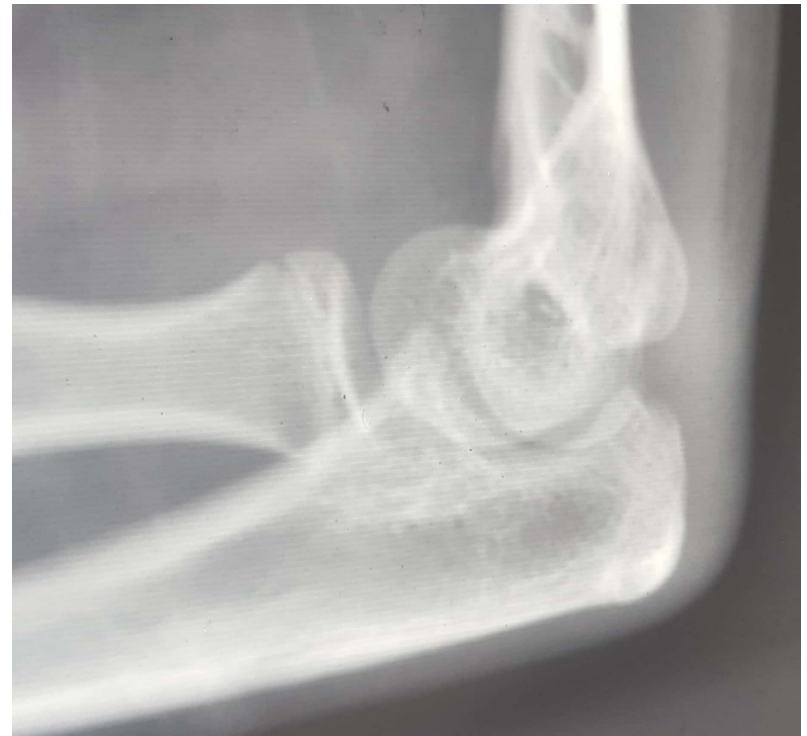
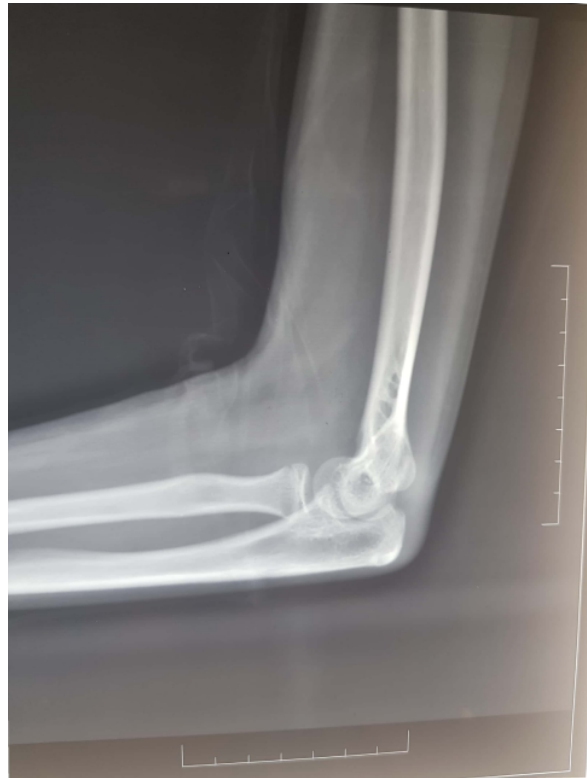
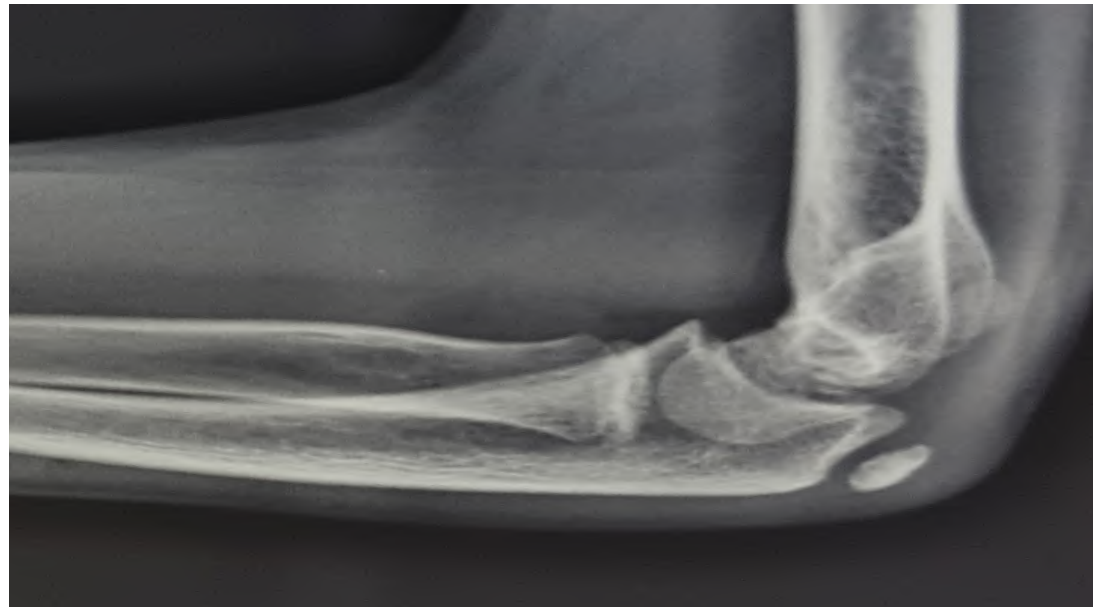FIG. 441.—The bones of the hand of a child, indicating the general plan of ossification.



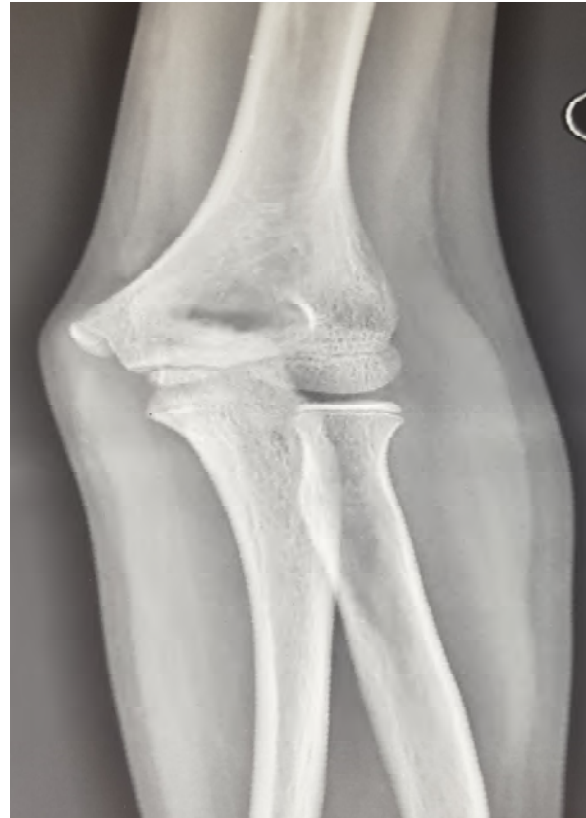ELBOW JOINT

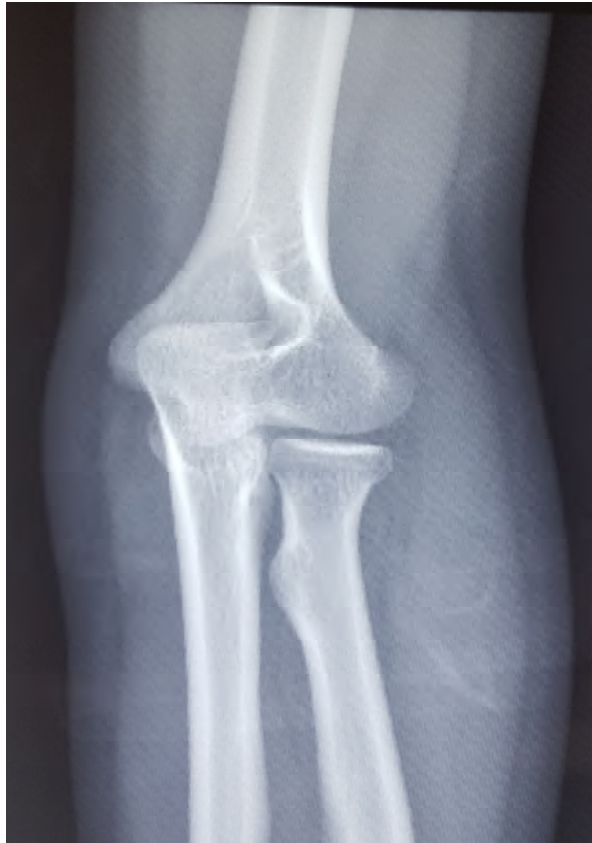
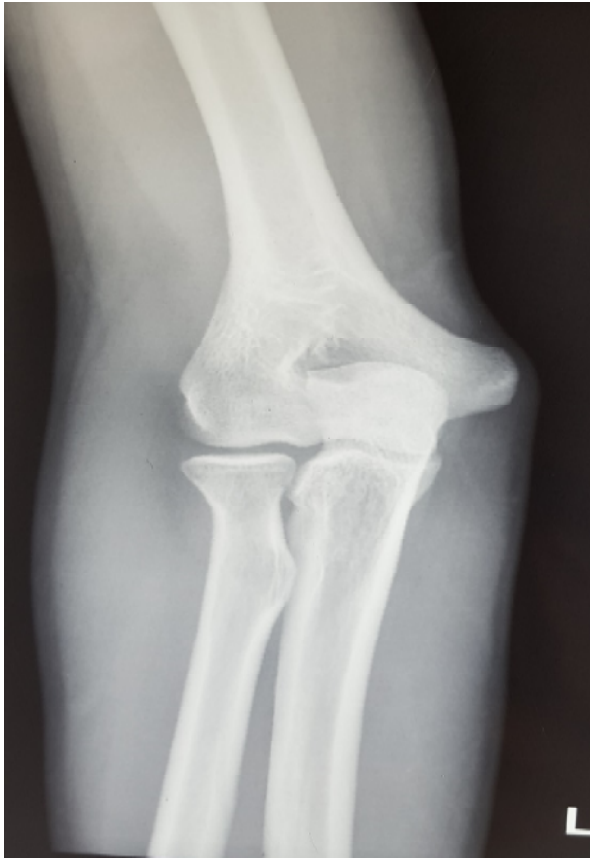

**OLECRANON
OR
ULNAR HEAD**



ELBOW JOINT

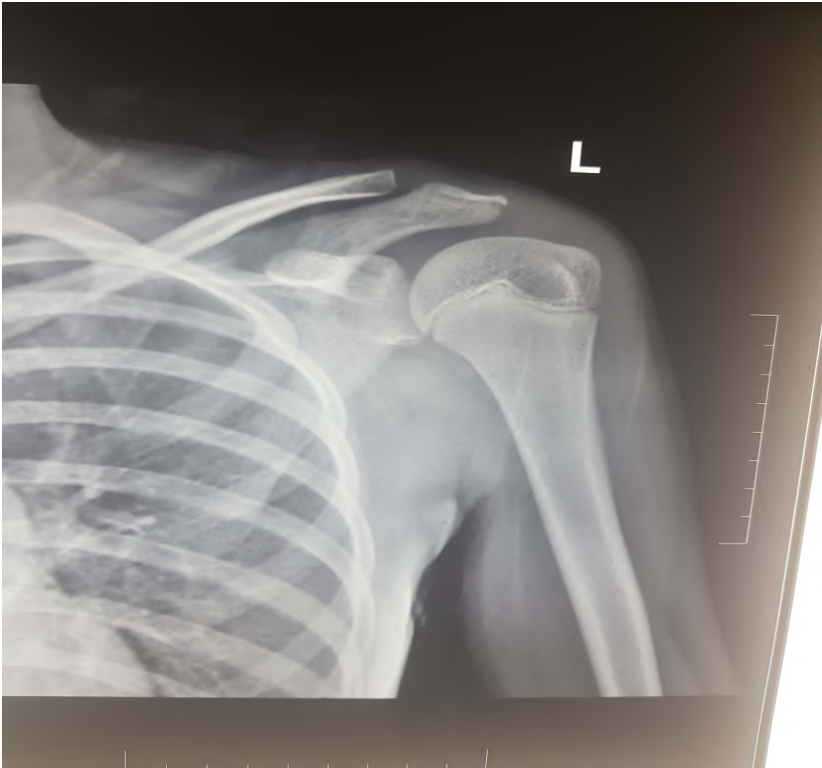



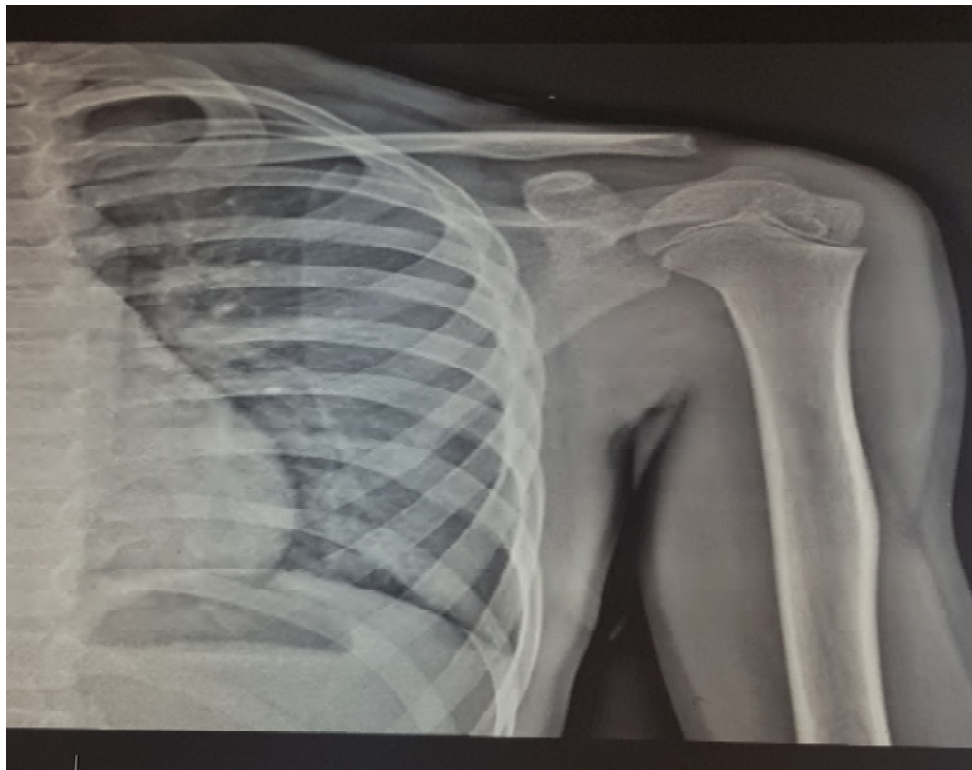
CRITOL

- ▷ C 1
- ▷ R 5
- ▷ I 6
- ▷ T 10
- ▷ O 11
- ▷ L 12

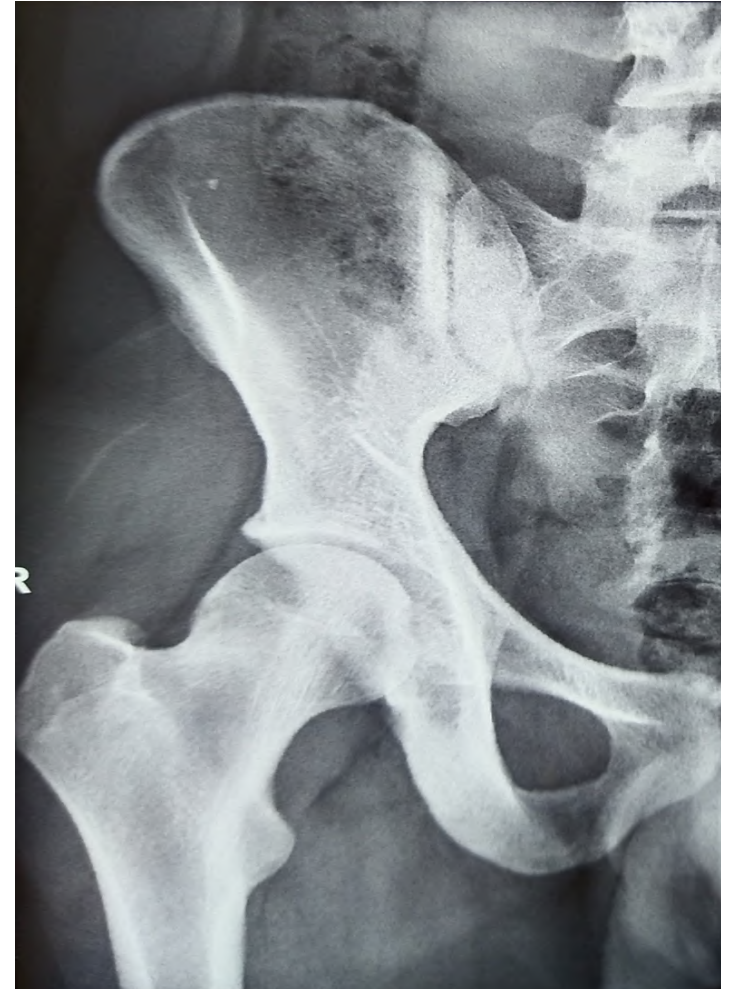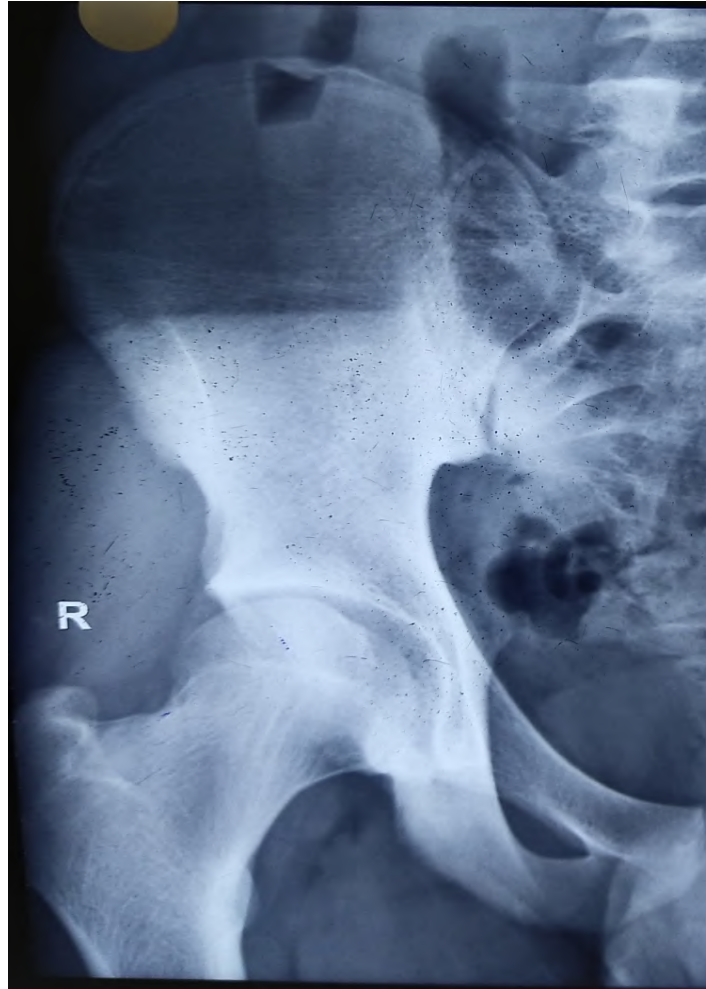
SHOULDER JOINT



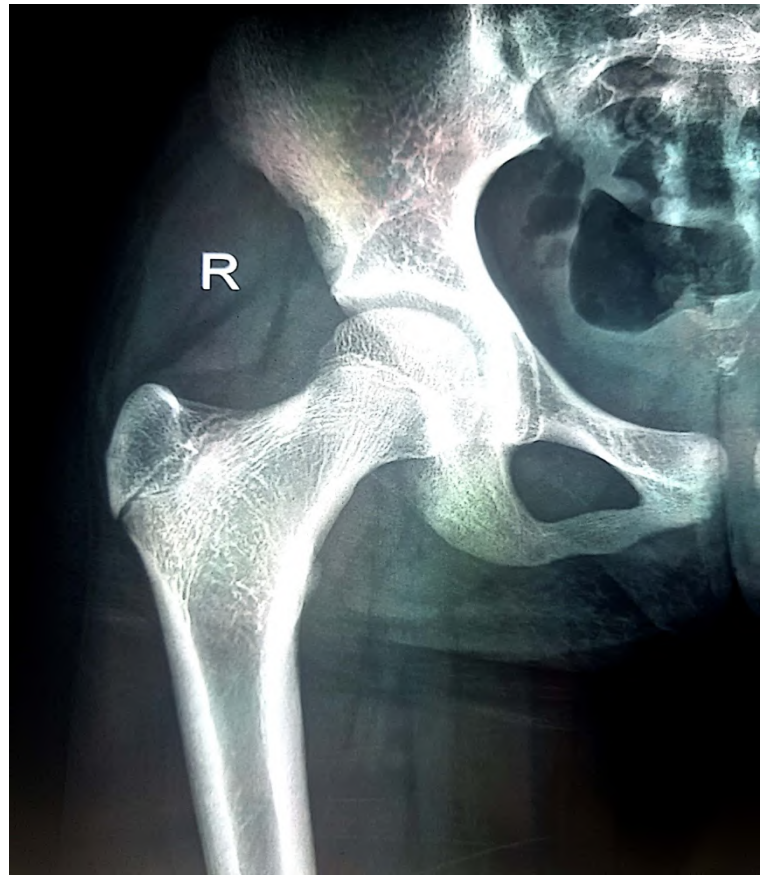
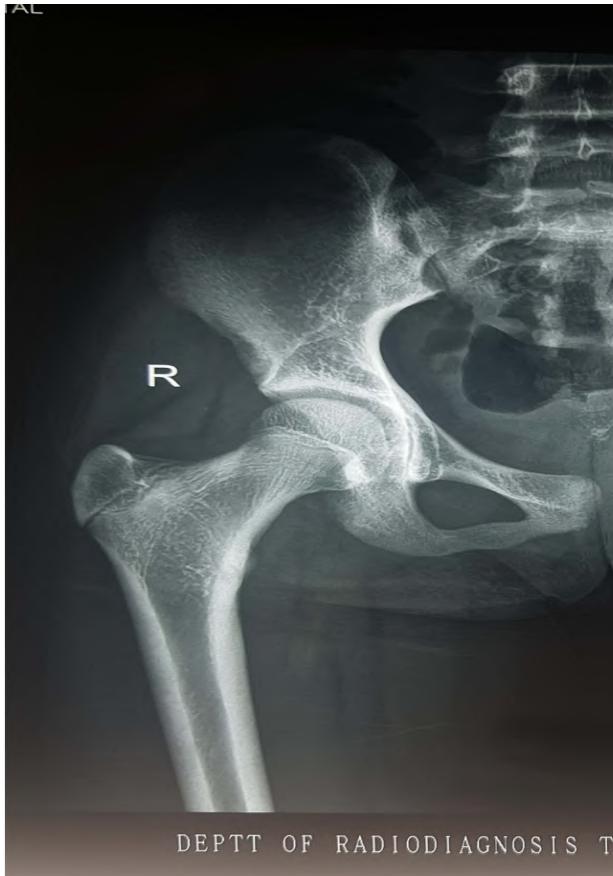SHOULDER JOINT



HIP BONE



HIP BONE



NAME /sex	Date of birth	X ray advised	Finding seen	description as per findings	Age inference
X/female	5/9/06	HAND & WRIST	1. Radius lower end appeared and not get fused yet.	in girls it appeared in 1 yrs and fused in 17-18 yrs	<17 yrs
			2. Ulna lower end appeared and not fused.	in girls it appeared in 5-6yrs and fused in 17yrs	<17 yrs
			3. Pisiform appeared	in girls it appears in 9-12 yrs	> 9 yrs
			4. bases of proximal phalanges appeared and not fused	in girls it appeared in 5-7 yrs and fused in 15-17 yrs	<15 yrs
		ELBOW JOINT	1. Radius head appeared and not fused	in girls it appeared in 5-6 yrs and fused in 13-14 yrs	<13 yrs


NAME /sex	Date of birth	X ray advised	Finding seen	description as per findings	Age inference
		Elbow joint continued..	2.Olecranon appeared and uniting	in girls it appeared in 9-11 yrs and fused in 13-15 yrs	>9 yrs and < 13 yrs as fusion started but completed i.e. around 12 yrs of age
		Shoulder Joint	1. head of humerus not fused	in girls it fused in 15-16 yrs	<15 yrs
			2. acromian process appeared but not fused	in girls it appeared in 12-14 yrs and fused in 13-16 yrs	>12 and <13 yrs

NAME /sex	Date of birth	X ray advised	Finding seen	description as per findings	Age inference
		Hip joint	1.greater trochanter not fused	in girls it appeared in 4yrs and fused in 14 yrs	<14 yrs
			2.head of femur is uniting but not completely fused	in girls it fused in 14-15 yrs	<14 yrs



Medicolegal importance of age

- ▷ Infanticide/foeticide
- ▷ Identification
- ▷ Eligibility for employment
- ▷ Attainment of majority
- ▷ Competency as witness
- ▷ Marriage contract
- ▷ Criminal responsibility

- 
- ▷ Judicial punishment
 - ▷ Management of property
 - ▷ Abduction
 - ▷ Rape
 - ▷ Criminal abortion

**Infanticide
/ foeticide**



Identification



ELIGIBILITY FOR EMPLOYMENT

No child who has not completed his 14th year shall be required or allowed to work in any factory.



Attainment of majority

Age of Majority

The age when a person acquires all the rights and responsibilities of being an adult. In most states the age is 18.

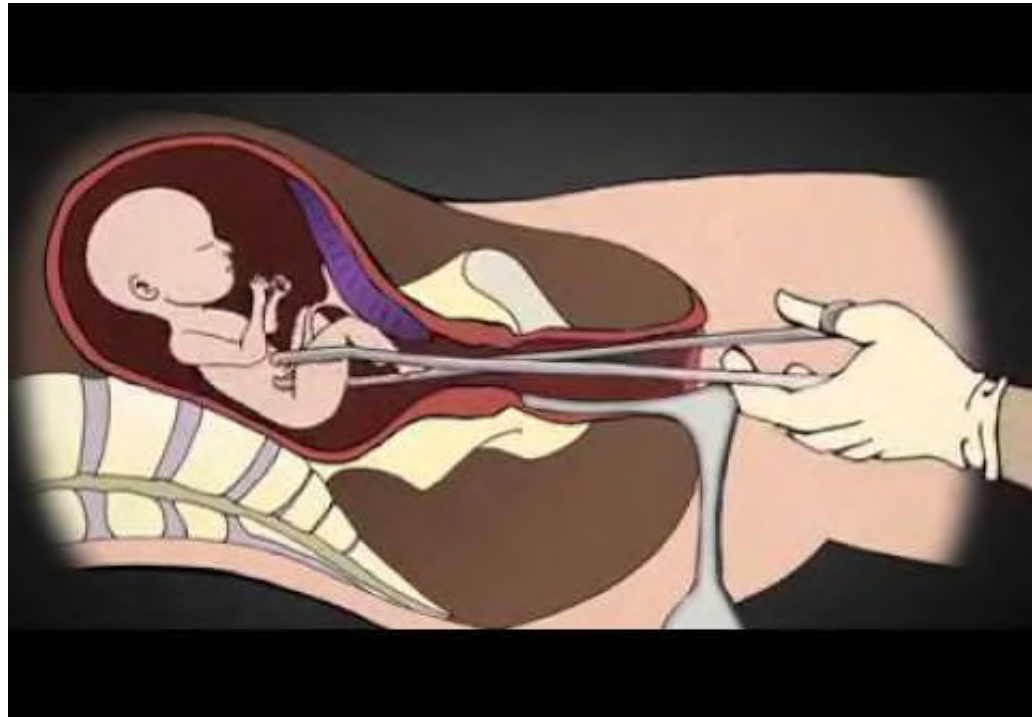


Competency as a witness

Any person is competent to testify as a witness , unless he is incapable of understanding the questions put to him or is unable to give any rational answers to questions asked , because of his tender years, old age, infirmity or disease- whether of mind or body or any other cause- vide sec.118 of IEA.



Criminal abortion



Rape



Management of property



Marriage contract



Criminal responsibility

Sec 82 IPC

Indian Railway Act

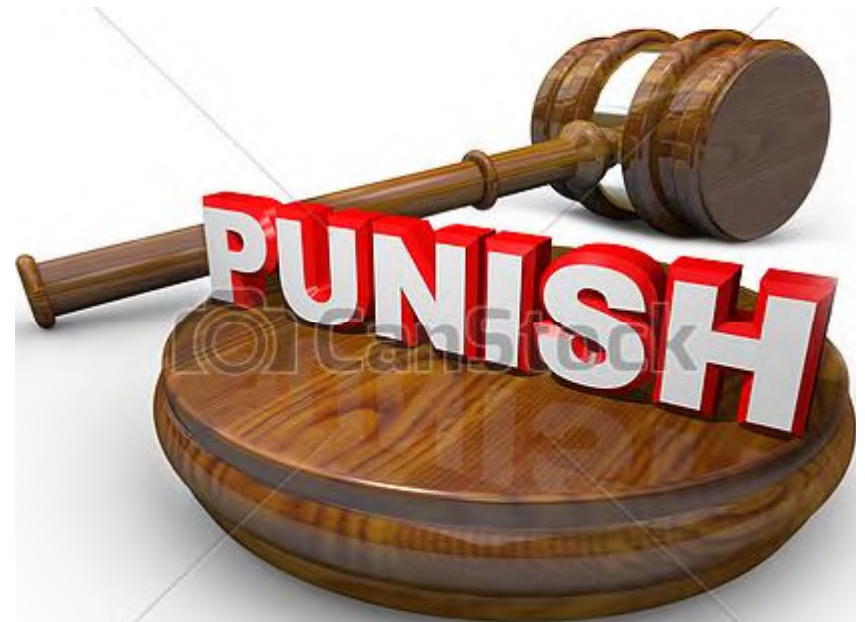Sec 83 IPC

Sec 89 IPC

Sec 87 IPC



Judicial Punishment



Abduction



**12 weeks of
pregnancy
(3 lunar
months)**

Till this duration decision regarding MTP can be done by one doctor alone .
Above 12 wks opinion of 2 doctors is required.



**20 weeks of
pregnancy
(5 lunar
months)**

Indications of MTP act covers max this duration.
Above 20 wks. pregnancy can be terminated
only on the grounds of mother's life in danger.

**28 week of
pregnancy
(7 lunar
months)**

- ▷ Foetus born after 28 wks,if does not show any sign of life is termed as still born foetus
- ▷ This is the age of viability



1year

- ▷ Till 1 year baby is infant
- ▷ Killing of such a baby amounts to infanticide



5 years

Above 5 y child becomes responsible
for his act as per Indian Railway Act

7 years

- ▷ Below 7 years child is not responsible for his criminal acts as below this age child is not able to understand the nature and consequences of the act
- ▷ Sec 82 IPC

**7 to 12
year**

- ▷ Presumed to be capable of committing an offence if the child has attained sufficient maturity of understanding to judge the nature and consequences of his conduct.
- ▷ Sec 83 IPC

12 years

- ▶ Can give consent for the act which is done for the benefit of the child ,even if the act ultimately causes harm to the child
- ▶ Less than 12 y can not give a valid consent to suffer any harm which may result from an act done in good faith for his benefit.



14 YEARS

FACTORY ACT states below 14 year is a child and can not be employed in factory jobs



**14 to 15
years**

Can be engaged in nonhazardous factory jobs during day hours



15 years

A person above 15 years of age can be employed in a factory like an adult if he has a fitness certificate.



16 years

- ▷ Boy Less than 16 –kidnapping
- ▷ A licensed vendor is not permitted to sell the intoxicating drugs to person below 16

18 years

- ▷ Attainment of majority but a person who is under the guardian appointed by court attains majority on completion of 21 years.
- ▷ A female less than 18 can not contract marriage as per child marriage restraint act 1978
- ▷ Sexual intercourse with a woman < 18 years even with consent is rape
- ▷ Age for voting in INDIA

25 years

Minimum age for contesting for the membership of parliament in Lok Sabha and for the member of any state legislative assembly in Vidhan Sabha

35 years

- ▷ Minimum age for appointment as the president of INDIA, vice president of INDIA and governor of any state
- ▷ No pre natal diagnostic techniques can be used or conducted in a women less than 35 y as per Prenatal diagnostic techniques (regulation and prevention of misuse)act 1994.