

POPLITEAL FOSSA

Dr Kaweri Dande

Resident

Department Of Anatomy

King George's Medical University, UP, Lucknow

DISCLAIMER:

- The presentation includes images which are either hand drawn or have been taken from google images or books.
- They are being used in the presentation only for educational purpose.
- The author of the presentation claims no personal ownership over images taken
- from books or google images.
- However, the hand drawn images are the creation of the author of the presentation

Learning objectives

- By the end of this teaching session all the students must be able to correctly:-
- Describe and demonstrate the location of the popliteal fossa
- Enumerate the boundaries, roof and floor of the popliteal fossa
- Enumerate the contents of the popliteal fossa
- Describe the relations of the popliteal fossa
- Draw a labelled diagram of the popliteal fossa
- Describe the applied anatomy of the popliteal fossa

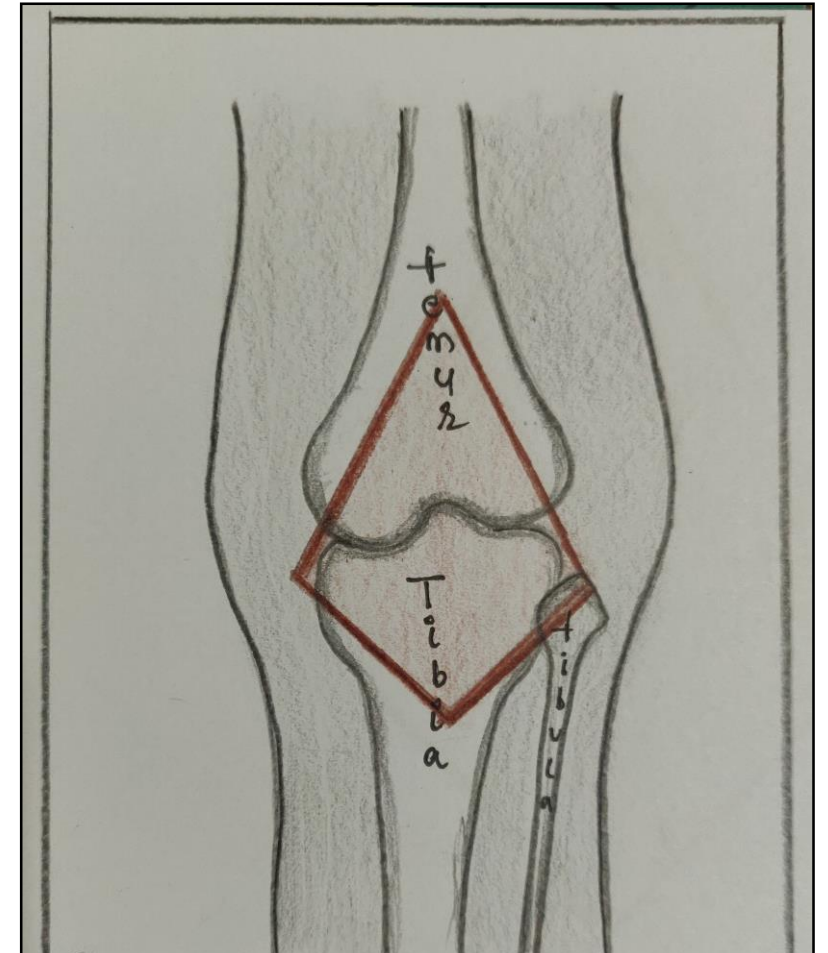
Preface 🔍

- Important transition area
- Between thigh and leg
- Passes structure between two



Location

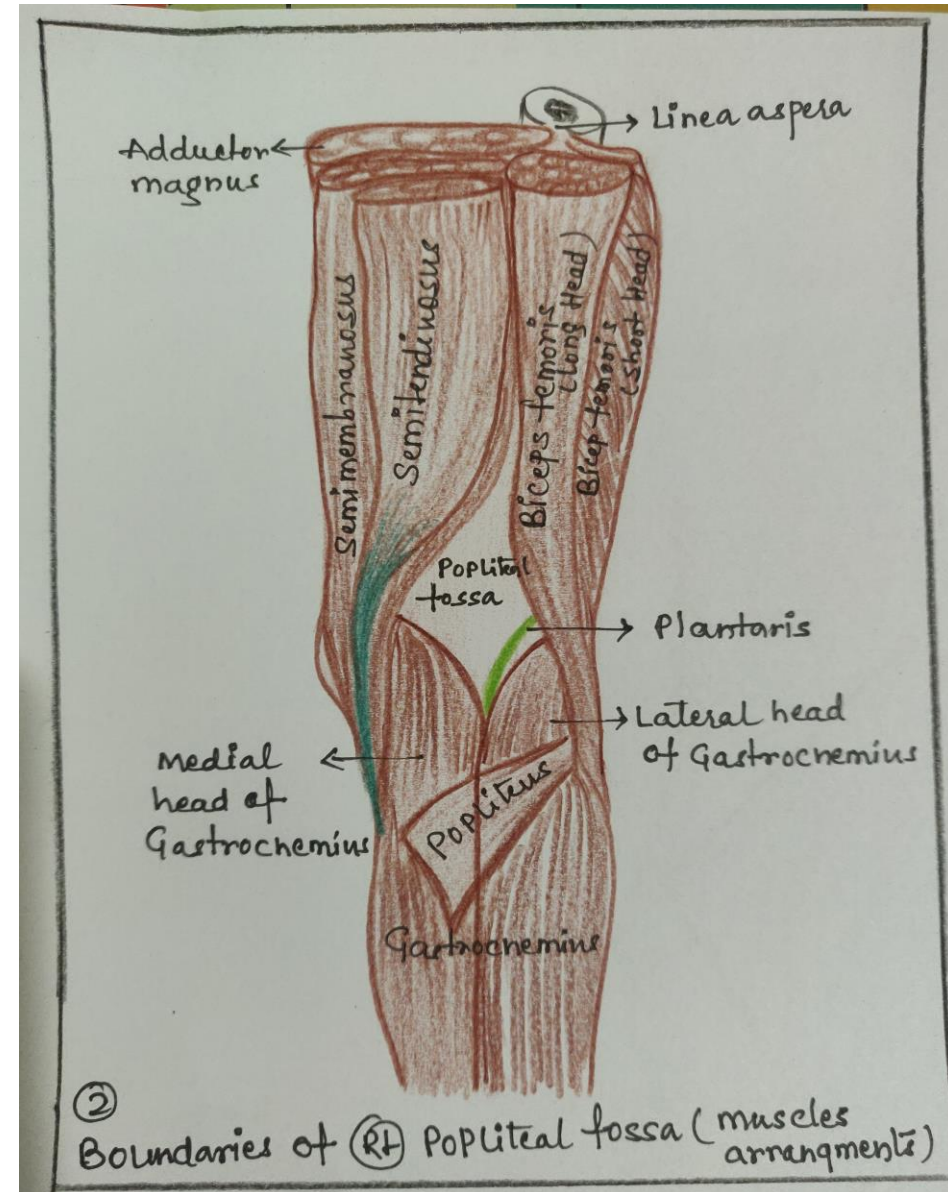
- Diamond shaped space
- Behind knee joint
- Formed between muscles
- Posterior compartment of thigh and leg



Outline of right popliteal fossa

Boundaries

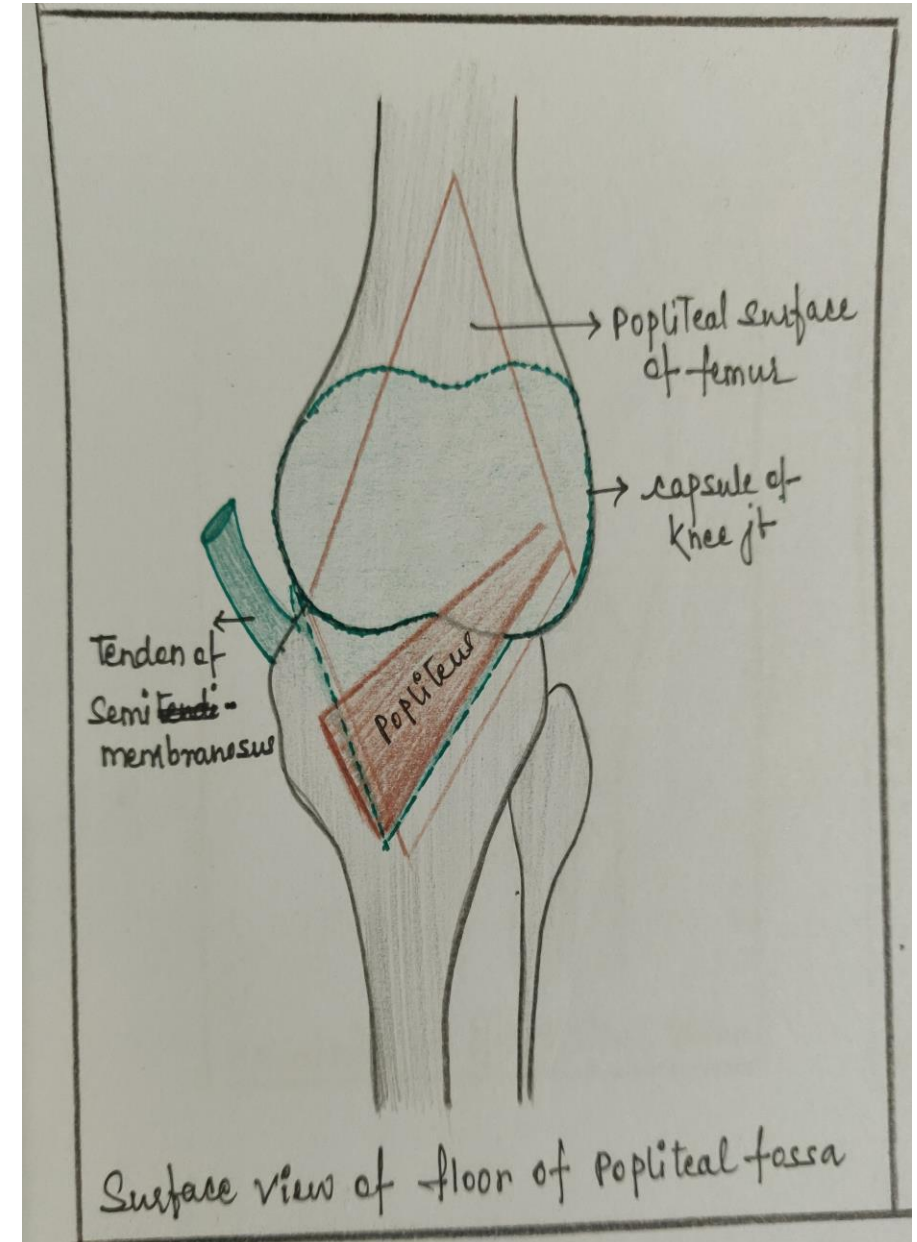
- Superolaterally: biceps femoris
- Superomedially: semitendinosus, semimembranosus
supplemented: gracilis, sartorius, adductor magnus
- Inferolaterally: lateral head of gastrocnemius, Plantaris
- Inferomedially: medial head of gastrocnemius



Floor

Above downwards

- Popliteal surface of femur
- Capsule of knee joint
- Oblique popliteal ligament
- Popliteal fascia
- Popliteal muscle



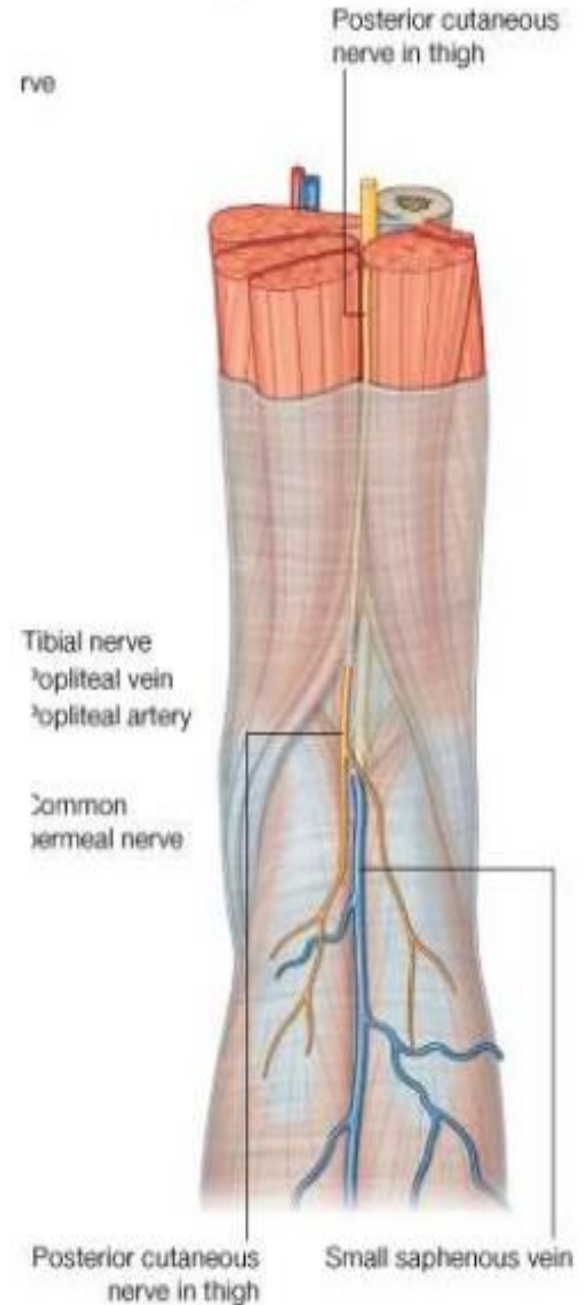
Roof

- Deep fascia(popliteal fascia)

- Continue

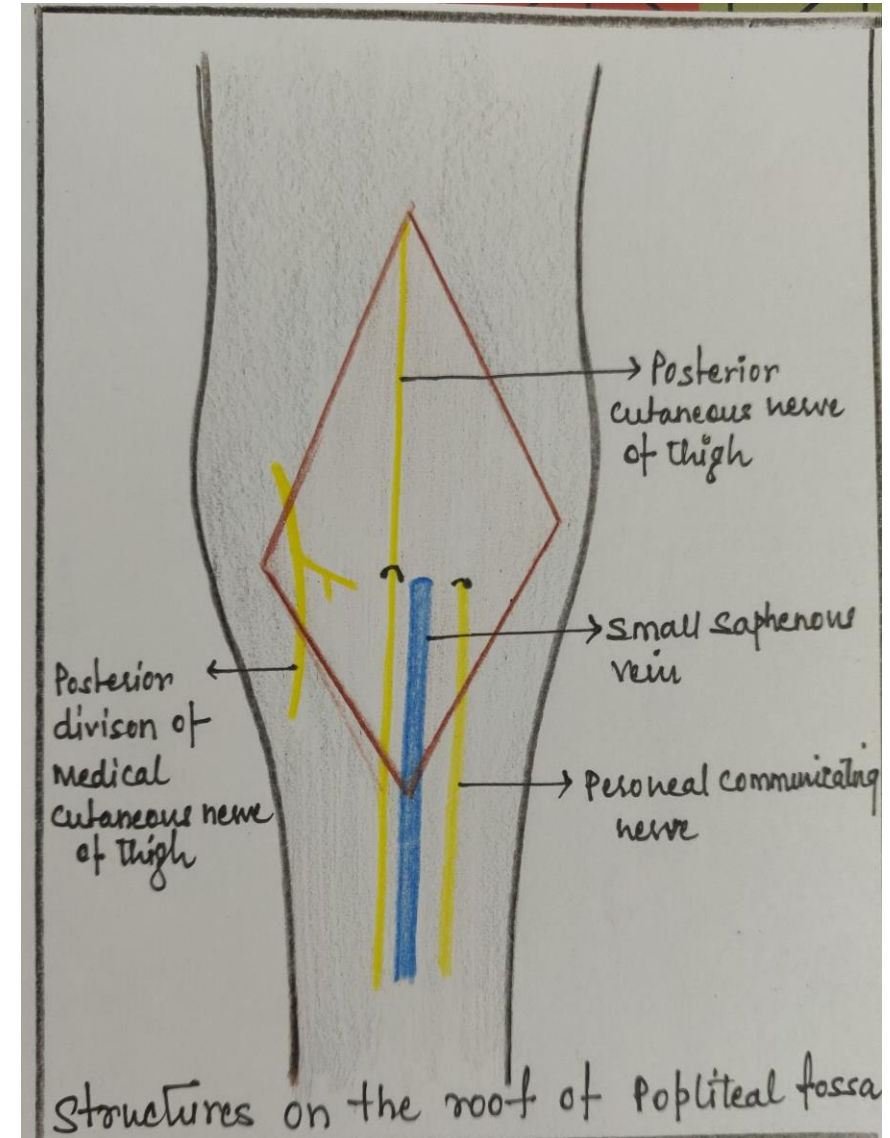
Above fascia lata of thigh

Below deep fascia of leg



Superficial Fascia Over Roof

- Short saphenous vein
- Cutaneous nerve
 - Posterior cutaneous nerve of thigh
 - Posterior division of medial cutaneous Nerve of thigh
 - Peroneal (sural) communicating nerve



Content

Popliteal vessels and its branch

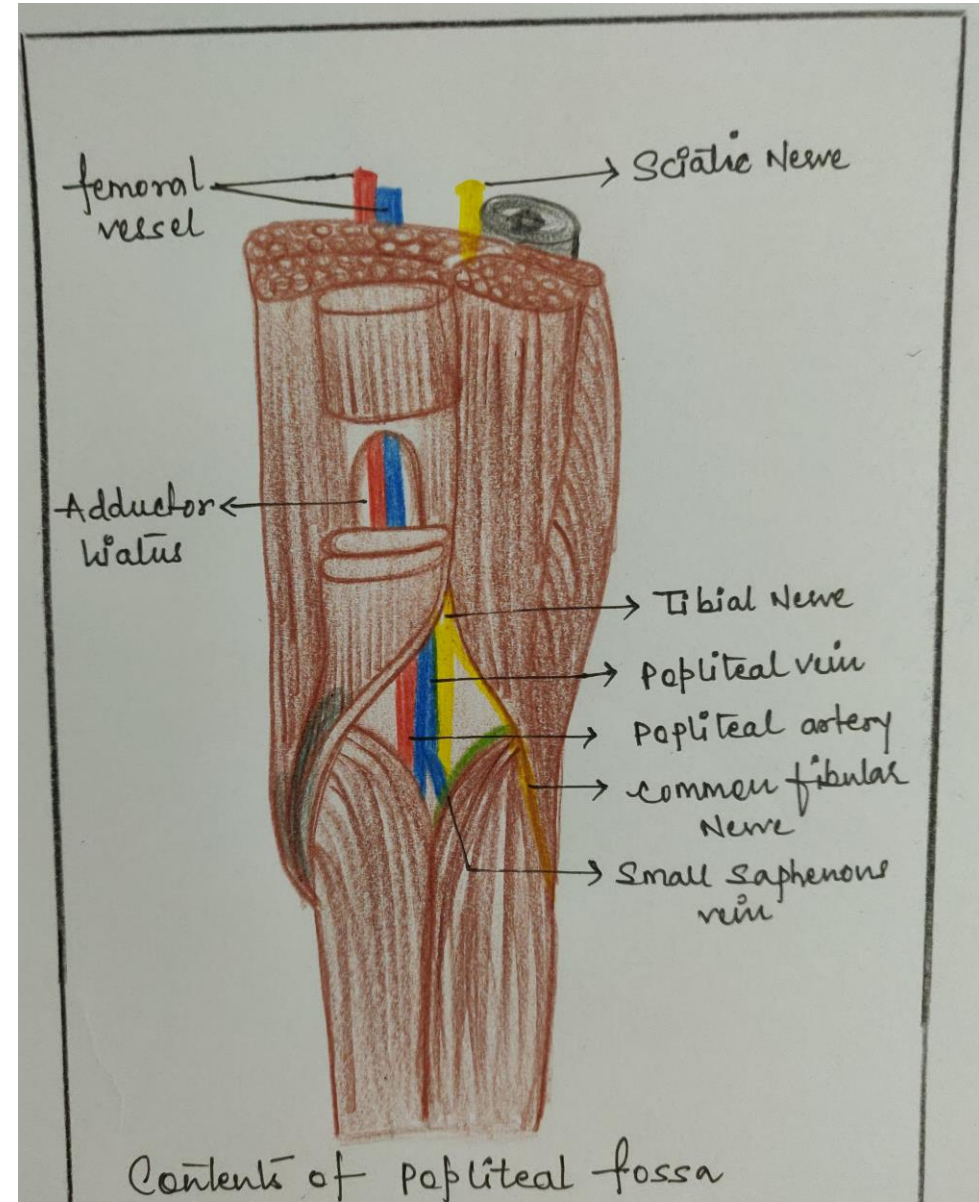
Tibial nerve and its branches

Common peroneal nerve and its branches

Genicular branch of obturator nerve

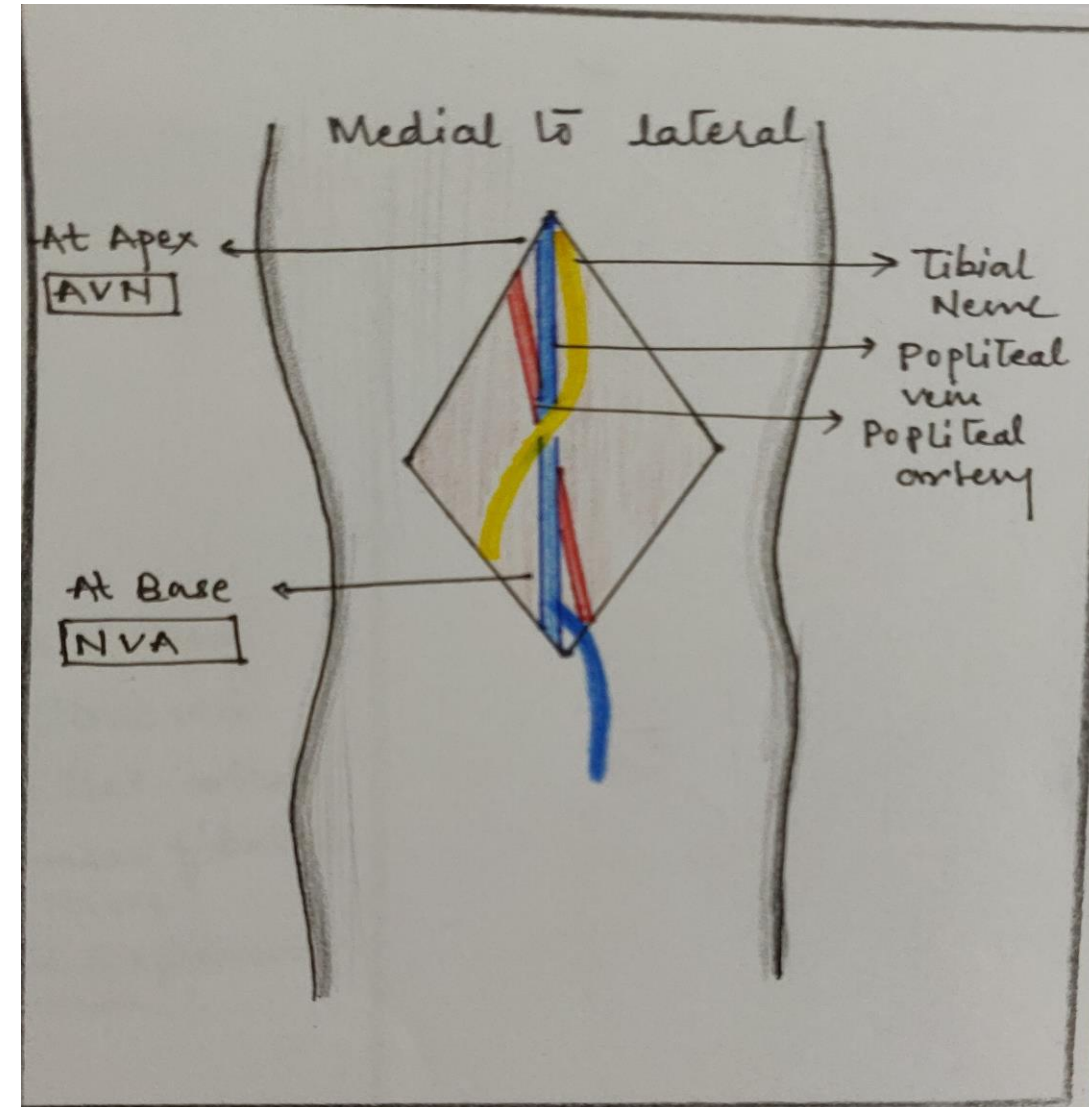
Popliteal lymph nodes

Fat



Relations In Fossa

- Upper part (medial to lateral)
Artery, vein, nerve
- Middle part (superficial to deep)
Nerve, vein, artery
- Lower part (medial to lateral)
Nerve, vein, artery



Popliteal vessels

- Popliteal artery

Deepest

Branches: muscular

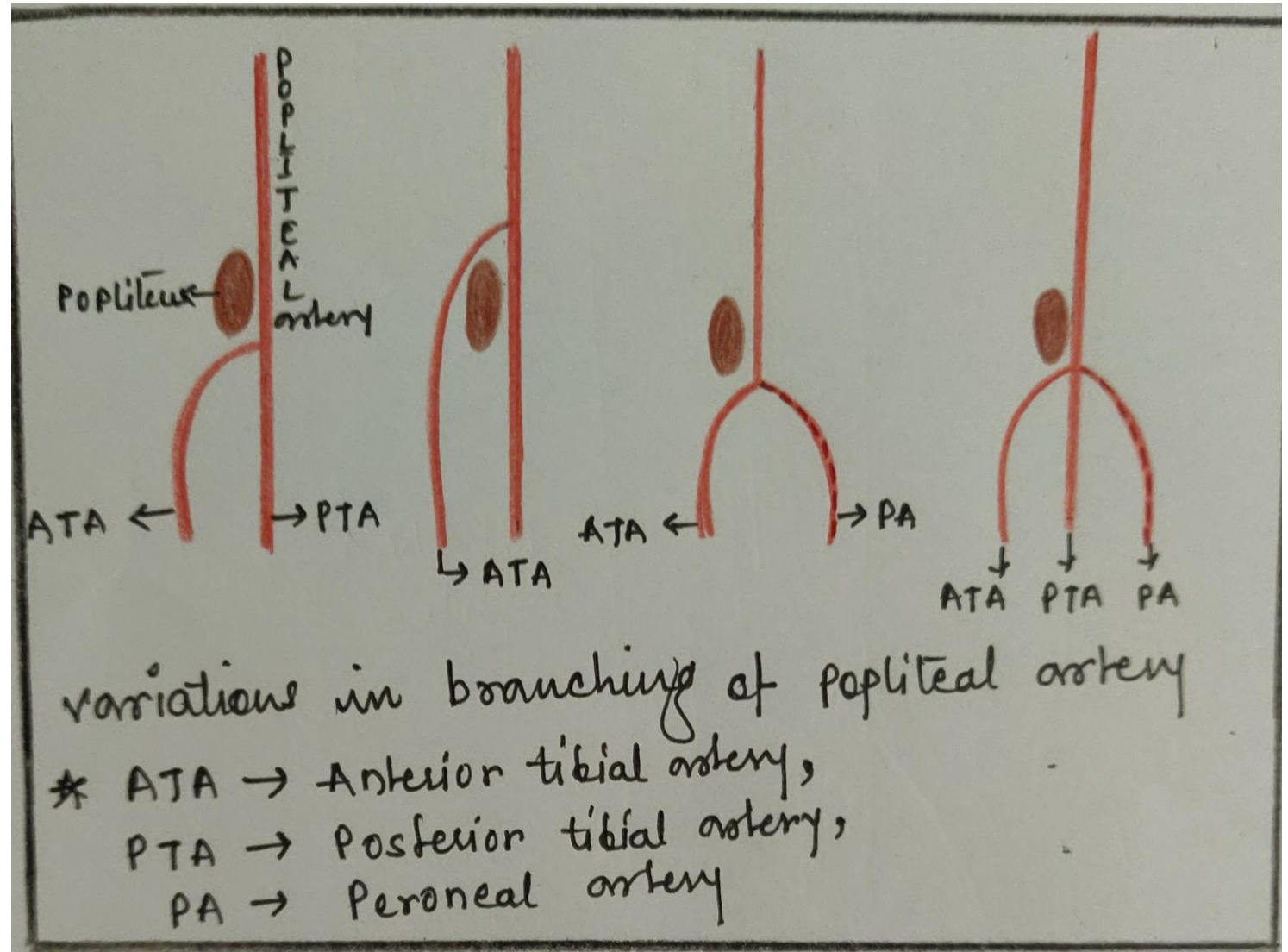
cutaneous

genicular

- Popliteal vein

Continues as femoral vein

Tributaries: small saphenous vein

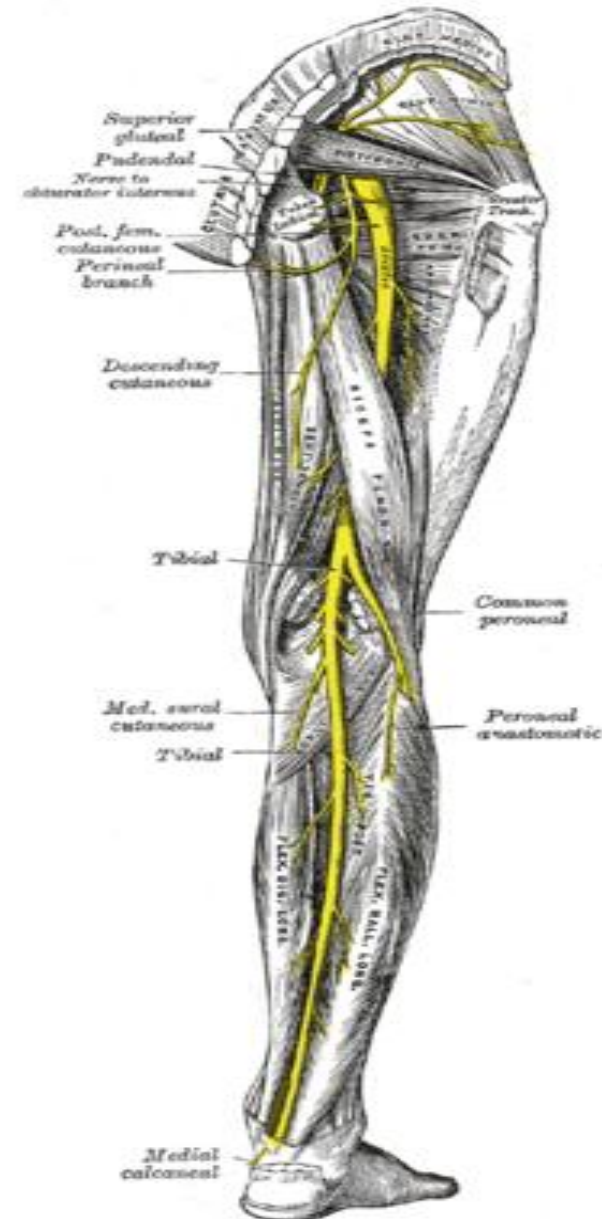


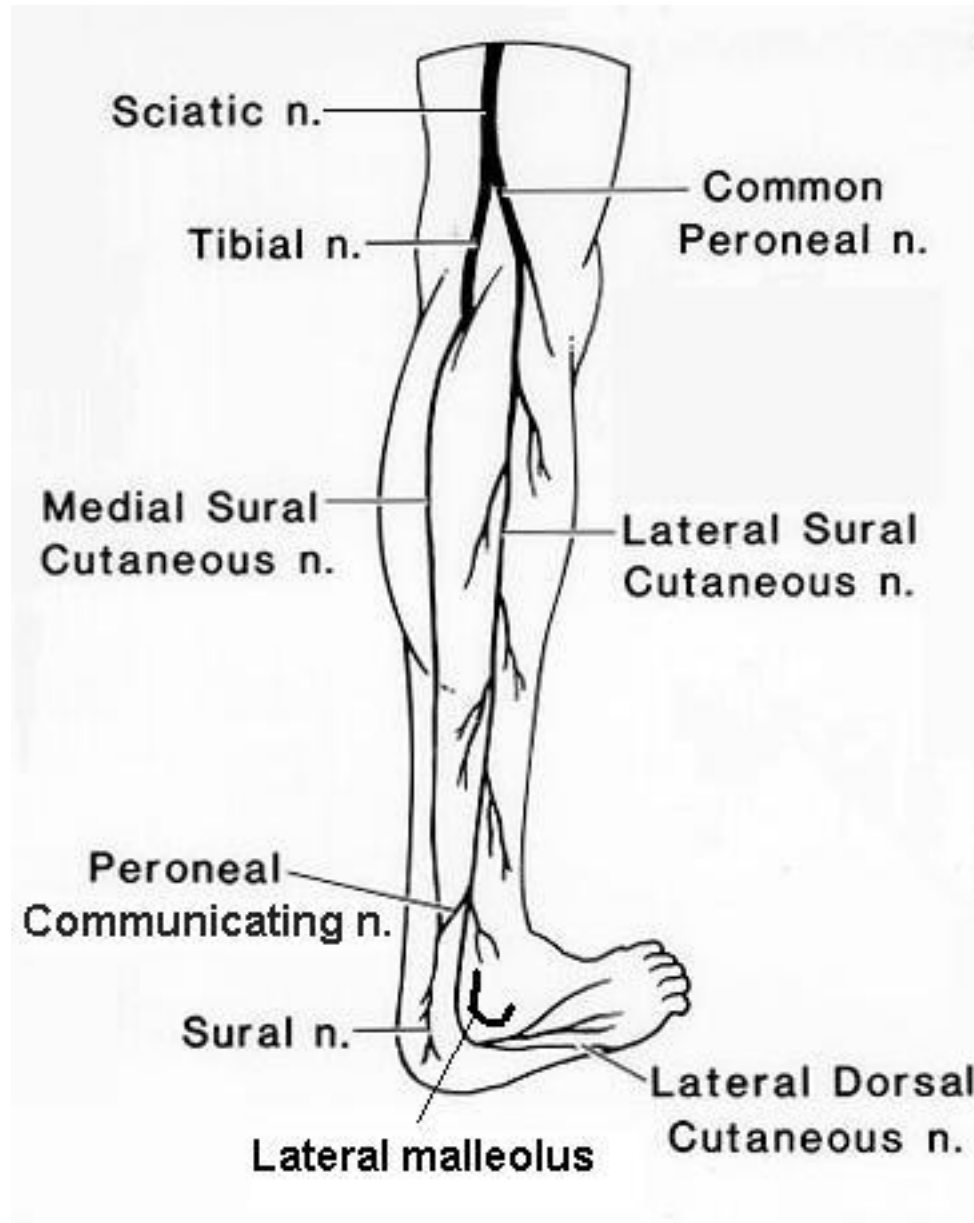
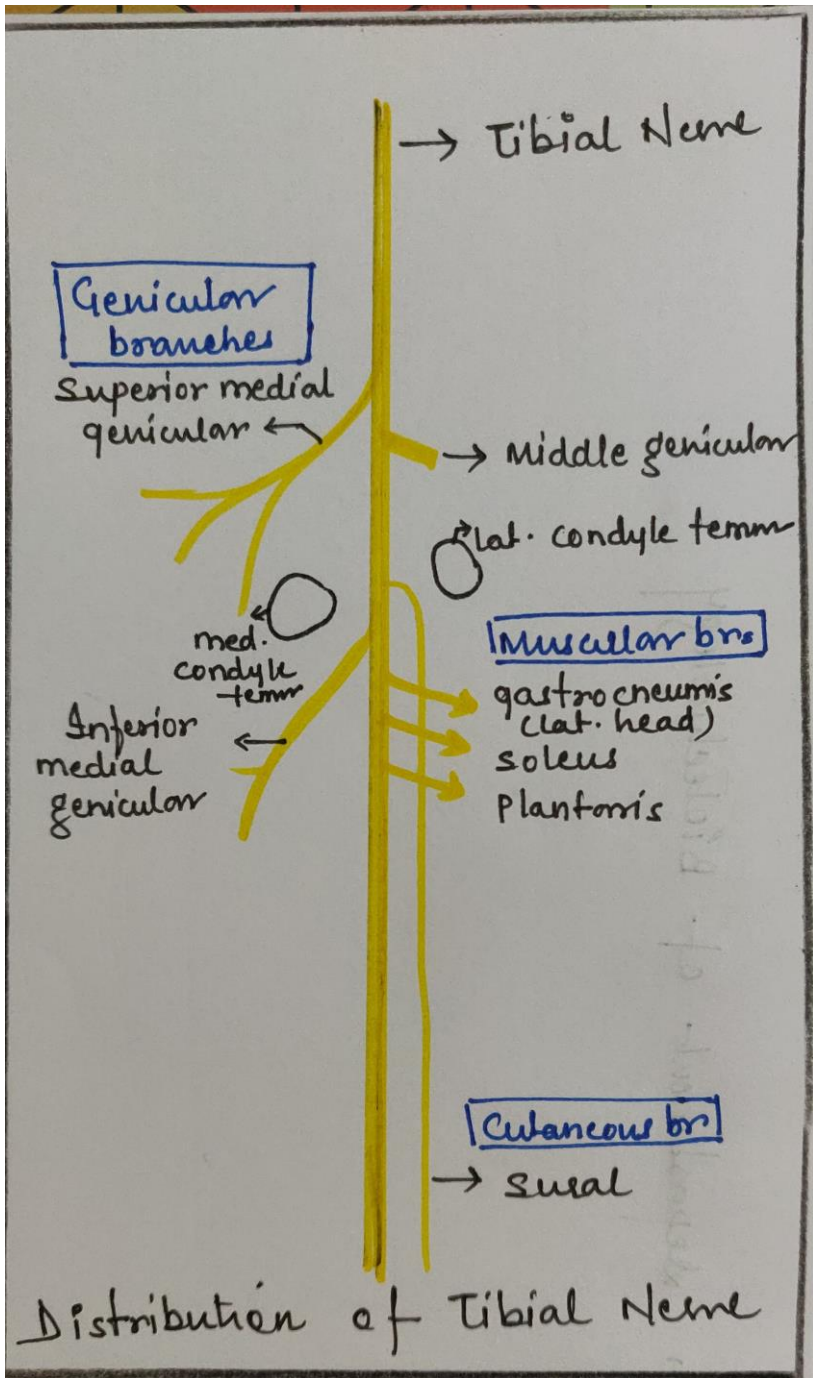
Nerve

- Tibial nerve(L4,L5,S1,S2,S3)
- Branches- genicular
muscular
cutaneous: sural

Common peroneal nerve(L4,L5,S1,S2)

- Branches- cutaneous: peroneal communicating
lat. cut. Nerve of calf
muscular(*may be*)
genicular



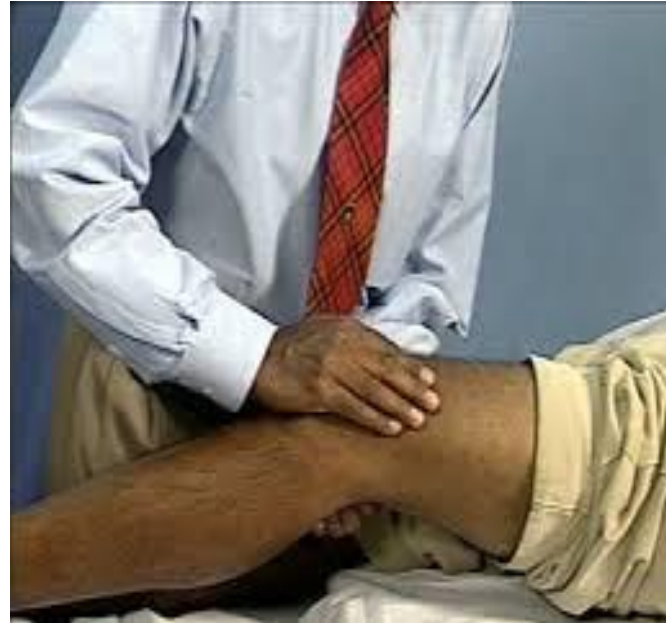

Common peroneal nerve

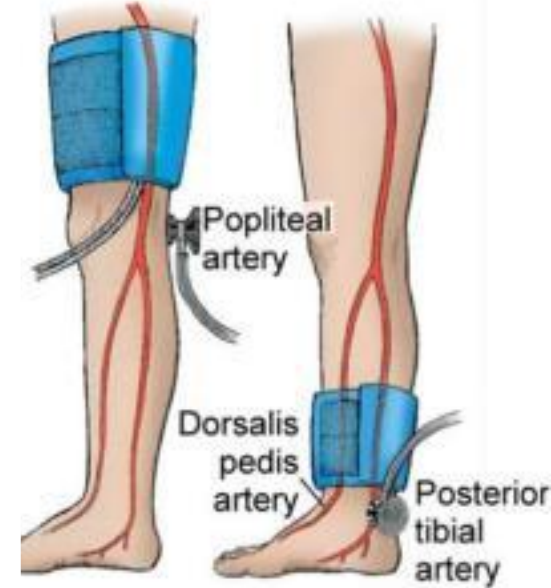
Applied Anatomy



- Pulsation Of Popliteal Artery
- Measurement Of Blood-Pressure
- Popliteal Artery Thrombosis
- Graft
- Aneurysm



Pulse recording



BP Recording



There's no such thing as useless knowledge. You never know what doors it's going to open up for you.

Ben Carson

“ quote fancy

Thank you